Lipodystrophies 101

Suat Hoon Tan, Hong Liang Tey and Joel Hua Liang Lim

Subtypes: ■ Lipodystrophy: lipoatrophy, lipohypertrophy

Key features

- Lipodystrophies are inherited or acquired disorders characterized by a paucity or complete absence of fat that may be generalized, partial, or localized; lipohypertrophy may accompany the lipoatrophy
- Though the terms lipodystrophy and lipoatrophy are often used interchangeably, lipoatrophy should be used specifically for selective loss of fat, with lipodystrophy implying a redistribution of fat, in part due to a hypertrophic compensation of the non-atrophic fat
- Lipodystrophy syndromes represent a heterogeneous group of disorders that are characterized by lipoatrophy ± fat accumulation in characteristic body distribution patterns
- Fat is a metabolically active organ, thus fat loss can be associated with metabolic derangements, which parallel the extent and duration of lipoatrophy
- Lipodystrophy is often accompanied by the metabolic syndrome, which includes insulin resistance, diabetes mellitus, hyperinsulinemia, dyslipidemia, cardiovascular disease, and hepatic steatosis
- In addition to the metabolic syndrome, systemic manifestations of generalized and partial lipodystrophy syndromes include hormonal abnormalities, organ dysfunction, anabolic features, glomerulonephritis, and autoimmune disorders
- A distinct syndrome of peripheral lipoatrophy, central obesity, breast hypertrophy, dorsocervical fat pad enlargement, hyperlipidemia and insulin resistance occurs in patients with HIV infection undergoing treatment with antiretroviral therapy (ART)
- Isolated or localized lipoatrophy can occur at the site of medication injection, trauma or pressure, in association with autoimmune connective tissue disease, or following certain panniculitic inflammatory or neoplastic processes
- Microscopically, there may be a complete absence of subcutaneous fat or a decrease in adipocyte size and number. An inflammatory panniculitis may be seen in early disease

INTRODUCTION

Lipodystrophy describes a heterogeneous group of diseases characterized by a selective fat loss in a characteristic body distribution pattern, often accompanied by secondary fat accumulation. Adipose tissue has crucial metabolic and endocrine functions, in addition to its role in mechanical protection. The loss of subcutaneous fat and a compensatory accumulation of visceral fat is closely associated with insulin resistance, diabetes mellitus, dyslipidemia, hypertension, and coronary artery disease. These metabolic abnormalities and their sequelae constitute the metabolic syndrome and underscore the important functions of fat, in its role as a diverse and crucial body organ.

More than a century after the first description of lipodystrophy[1] and then delineation of generalized lipodystrophy into congenital and acquired forms[2], the genetic bases of several of the inherited lipodystrophies have now been elucidated. Mutations have been found in genes ranging from those encoding proteins essential for adipocyte differentiation to those encoding nuclear lamins (see below).

Clinically, lipodystrophy can be broadly classified into inherited or acquired forms and then further subclassified based on the extent of fat loss, in conjunction with genetic mutations, age of onset, and systemic manifestations (Fig. 101.1 & Table 101.1). Based upon the distribution pattern, lipodystrophy may be subdivided into three major groups: (1) generalized; (2) partial (extensive, but not generalized); and (3) localized (involving an isolated area).

Localized lipodystrophy, which may be due to injections of medications or vaccines, pressure, previous surgery, trauma or panniculitis, is the most commonly encountered form. It typically presents as lipoatrophy but occasionally lipohypertrophy develops, e.g. at sites of insulin injection (see Table 21.22). Less often, lipodystrophy associated with antiretroviral therapy (ART) for human immunodeficiency virus (HIV) infection[3] and with administration of immune checkpoint inhibitors are seen. Dermatologists may also play a key role in diagnosing acquired generalized lipodystrophy and its preceding panniculitis. Finally, there are several rare genetic syndromes that will be discussed (see Table 101.1).

PATHOGENESIS

Adipose tissue functions as an endocrine organ via its secretion of hormones and adipocytokines, such as leptin, TNF, interleukin (IL)-6, and adiponectin. Altered expression and activity of these factors play a role in the development of insulin resistance and other metabolic sequelae seen in lipodystrophic syndromes, which are similar to those observed in the metabolic syndrome and obese individuals[4,5].

There appears to be a final common pathway of defective adipocyte triglyceride storage in conditions characterized by fat loss as well as fat excess. This defect can result from impaired triglyceride synthesis due to an enzyme deficiency (e.g. 1-acylglycerol-3-phosphate *O*-acyltransferase 2), defective adipocyte development caused by mutations in genes critical to adipocyte differentiation (e.g. *BSCL2/seipin, PPARG, LMNA*), adipocyte apoptosis, or autoimmune- or drug-mediated adipocyte destruction. These various processes impair normal adipocyte differentiation, development, lifespan, and/or function[6].

The destruction or impaired differentiation of adipocytes leads to a cascade of hormonal and metabolic consequences. Adiponectin, the protein product of *ADIPOQ*, is expressed in and secreted exclusively by differentiated adipocytes. It plays a positive role in regulating insulin sensitivity and glucose and lipid homeostasis. Plasma adiponectin levels are inversely correlated with fasting insulin levels and insulin resistance[7]. Serum adiponectin and leptin levels are reduced both in murine models of lipoatrophy with insulin resistance and in humans with congenital and acquired lipodystrophies,[8] including HIV/ART-related lipodystrophy[9,10]. Leptin replacement has been shown to reverse insulin resistance in mouse models with a deficiency of mRNAs that encode leptin.[11] This replacement also results in significant and sustained improvements in hyperglycemia, dyslipidemia, and hepatic steatosis in patients with different forms of lipodystrophy[12,13].

Congenital Generalized Lipodystrophy (Berardinelli–Seip Congenital Lipodystrophy, Berardinelli–Seip Syndrome)

Congenital generalized lipodystrophy (CGL) is an autosomal recessive disorder with four known genetic subtypes. The two major forms, types 1 and 2, are due to mutations in *AGPAT2*, which encodes 1-acylglycerol-3-phosphate *O*-acyltransferase 2, and *BSCL2/seipin*, respectively (see Table 101.1). It has been postulated that these genetic mutations cause lipodystrophy primarily by affecting adipocyte differentiation or lipid droplet formation in adipose tissue. In type 1, aberrant AGPAT2

Downloaded for Anonymous User (n/a) at Egyptian Knowledge Bank from ClinicalKey.com by Elsevier on March 10, 2024. For personal use only. No other uses without permission. Copyright ©2024. Elsevier Inc. All rights reserved.

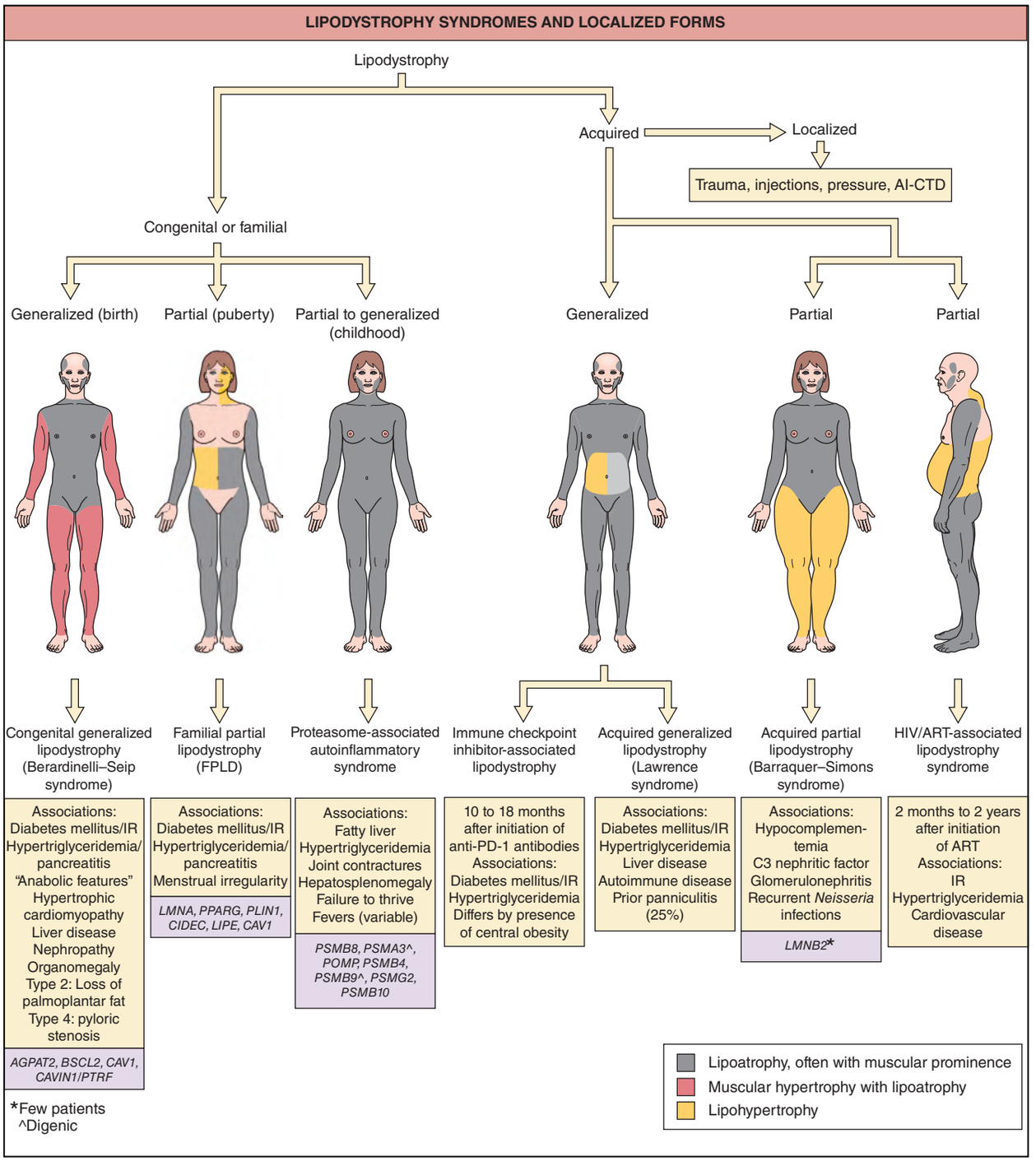

Fig. 101.1 Lipodystrophy syndromes and localized forms. Schematic representation of the predominant sites of lipoatrophy and lipohypertrophy. Additional syndromes, including familial partial lipodystrophy with mandibuloacral dysplasia, are outlined in Table 101.1. Tables 63.9 and 63.10 review progeroid syndromes in which lipoatrophy can be seen. AI-CTD, autoimmune connective tissue disease; ART, antiretroviral therapy; IR, insulin resistance; PD, programmed cell death. *AGPAT2*, encodes 1-acylglycerol-3-phosphate *O*-acyltransferase 2 (triglyceride and phospholipid synthesis); *BSCL2*, encodes seipin (lipid droplet formation); *CAV1*, encodes caveolin 1 (binds fatty acids and translocates them to lipid droplets); *CAVIN1/PTRF*, encodes caveolae associated protein 1 (biogenesis of caveolae and expression of caveolins 1 and 3); *CIDEC*, encodes cell death-inducing DNA fragmentation factor-like effector C (adipocyte apoptosis); *LIPE*, encodes lipase E, hormone sensitive type (hydrolysis of triglycerides to free fatty acids); *LMNA*, encodes lamins A/C (structural integrity of the nuclear lamina); *LMNB2*, encodes lamin B2 (structural integrity of the nuclear lamina); *PLIN1*, encodes perilipin 1 (formation, maturation, and function of lipid droplets within adipocytes); *POMP*, encodes proteasome maturation protein; *PPARG*, encodes peroxisome proliferator-activated receptor-gamma (essential role in lipogenesis); *PSMA3*, encodes proteasome subunit alpha 3; *PSMB4, -B8, -B9, -B10*, encode proteasome subunit beta 4, 8, 9, 10; *PSMG2*, encodes proteasome subunit gamma 2.

enzyme activity causes a marked reduction in triglyceride and phospholipid synthesis, resulting in abnormal adipocyte function[14]. In type 2, *BSCL2* mutations affect the endoplasmic reticulum membrane protein seipin which is critical for lipid droplet morphology.

In types 3 and 4 CGL, genetic mutations alter the function of caveolae, which are invaginations of the plasma membrane involved in signal transduction and endocytosis, including internalization of the insulin receptor. Patients with type 3 CGL have mutations in *CAV1* which encodes caveolin 1[15]; caveolins are essential components of caveolae and caveolin 1 binds fatty acids and translocates them to lipid droplets. Type 4 CGL is due to mutations in *CAVIN1/PTRF*, whose protein product is involved in the biogenesis of caveolae and the expression of caveolins 1 and 3[16].

Differences in the molecular basis of CGL may account for the phenotypic heterogeneity[17]. *AGPAT2* has been found to be highly expressed in human omental adipose tissue, which may explain the preferential loss

Downloaded for Anonymous User (n/a) at Egyptian Knowledge Bank from ClinicalKey.com by Elsevier on March 10, 2024. For personal use only. No other uses without permission. Copyright ©2024. Elsevier Inc. All rights reserved.

LIPODYSTROPHY SYNDROMES							
Syndrome	**Age of onset**	**Sex**	**Genetics**	**Distribution of fat changes**	**Metabolic derangements**	**Systemic associations**	**Additional cutaneous and systemic features**
Inherited							
Congenital generalized lipodystrophy (CGL; Berardinelli–Seip syndrome)	Birth	F = M	AR Type 1: *AGPAT2* Type 2: *BSCL2/seipin* Type 3: *CAV1* Type 4: *CAVIN1/PTRF*	Fat: face, trunk, extremities, viscera Types 1, 3, 4: loss of metabolically active adipose tissue in the skin and viscera, but preservation of mechanical adipose tissue (palmoplantar, retro-orbital) Type 2: both metabolically active and mechanical adipose tissue are lost Types 1, 2: lack of bone marrow fat Types 3, 4: preserved bone marrow fat	+++: IR, DM, ↑ TG; anabolic features; ↑ metabolic rate	Type 3: associated with vitamin D resistance	Hypertrophic cardiomyopathy, liver failure/cirrhosis, acute pancreatitis, organomegaly,osteosclerosis, proteinuric nephropathy (see Table 101.3) More severe disease in type 2, with higher incidence of intellectual disability and cardiomyopathy Type 4: prominent skin veins, cardiac conduction defects, pyloric and esophageal stenosis, muscle weakness
Familial partial lipodystrophy (FPLD; previously referred to as Köbberling–Dunnigan syndrome)	Puberty	F > M	AD FPLD1 (Köbberling type): not known FPLD2 (Dunnigan type): *LMNA* [lamin A/C] FPLD3: *PPARG* FPLD4: *PLIN1* FPLD7: *CAVI* AR* FPLD5: *CIDEC* FPLD6: *LIPE*	FPLD1: ↓ fat on extremities ± ↑ fat on face/neck, trunk FPLD2: ↓ fat on extremities ± trunk, ↑ fat on face/neck (double chin), muscular hypertrophy FPLD3: ↓ fat on extremities/buttocks (less severe than FPLD2); trunk/viscera spared FPLD4: ↓ fat on lower extremities with small adipocytes and increased fibrosis of adipose tissues FPLD5: ↓ fat on lower extremities/buttocks; small, multilocular lipid droplets histologically FPLD6: ↓ fat on lower extremities, ↑ fat of abdomen and axillae	IR, DM, ↑ TG, ↓ HDL (more severe in FPLD3 than FPLD2)	None preceding	Chylomicronemia syndrome with acute pancreatitis, eruptive xanthomas Clinical findings and metabolic complications more severe in women
Familial partial lipodystrophy with mandibuloacral dysplasia (MAD)	Childhood or puberty	M > F	AR Type A: *LMNA* Type B: *ZMPSTE24*	fat on extremities Type B – may have generalized lipodystrophy	IR, DM, ↑ TG, ↓ HDL in some patients	None preceding	Premature aging, hypoplasia of mandible, clavicles and terminal digits, short stature, scleroderma-like skin lesions with mottled skin pigmentation
Proteasome-associated autoinflammatory disorders (PRAAS; PRAAS1 has also been referred to as CANDLE syndrome and Nakajo–Nishimura syndrome)	Childhood	M = F	AR PRAAS1: *PSMB8, PSMA3* (digenic) PRAAS2: *POMP* PRAAS3: *PSMB4, PSMB9* (digenic) PRAAS4: *PSMG2* PRAAS5: *PSMB10*	Common features: ↓ facial fat, partial lipoatrophy involving upper half of body Occasionally, generalized lipoatrophy	↑ TG, ↓ HDL cholesterol	None preceding	Panniculitis, pernio-like lesions, eyelid edema and erythema Hepatosplenomegaly, basal ganglia calcifications (for additional features see text)

Table 101.1 Lipodystrophy syndromes.

Continued

Downloaded for Anonymous User (n/a) at Egyptian Knowledge Bank from ClinicalKey.com by Elsevier on March 10, 2024. For personal use only. No other uses without permission. Copyright ©2024. Elsevier Inc. All rights reserved.

LIPODYSTROPHY SYNDROMES							
Syndrome	**Age of onset**	**Sex**	**Genetics**	**Distribution of fat changes**	**Metabolic derangements**	**Systemic associations**	**Additional cutaneous and systemic features**
Acquired							
Acquired generalized lipodystrophy (Lawrence syndrome)	Childhood or adolescence	F > M 3 : 1	None known	↓ Fat: face, trunk, extremitiesPreservation of fat within the bone marrow	++: IR, DM, ↑ TG (correlates with the degree of lipodystrophy)	1/3 have a preceding autoimmune disease (e.g. juvenile dermatomyositis, Sjögren syndrome) or infection; 25% have a preceding panniculitis; rarely associated with CVID	Liver failure/cirrhosis, proteinuric nephropathy
Acquired partial lipodystrophy (Barraquer–Simons syndrome)	Childhood or adolescence Rarely adults	F > M 3 : 1	Sporadic or AD: *LMNB2* (Lamin B2)	Fat: face, upper extremities, trunk, with spread in a cephalocaudal direction Spares lower extremities Fat: hips and legs Hemilipodystrophic variants	Rare IR, DM, ↑ TG	Often preceded by a febrile illness; 1/5 have mesangiocapillary glomerulonephritis Almost all have low levels of C3 and presence of circulating C3 nephritic factor Autoimmune disease associations include SLE, dermatomyositis	Sequelae of renal abnormalities
HIV/ ART-associated lipodystrophy syndrome	2 months to 2 years after initiation of combination antiretroviral therapy (ART) Adults > children	M = F overall, F > M central adiposity	None known	Fat: face, extremities Fat: central (trunk/viscera), dorsocervical ("buffalo hump"), breasts Lipomas (e.g. pubic)	++: IR, ↑ TG, ↑ LDL, ↓ HDL; ± DM	HIV infection	Cardiovascular disease
Immune checkpoint inhibitor-associated lipodystrophy	Reflects underlying neoplasm	Reflects underlying neoplasm	–	↓ Fat: face, limbs, ↑ fat of abdomen	IR, DM, ↑ TG	Underlying neoplasm	Hepatic steatosis

*Provisional for FPLD5 and FPLD6.

Table 101.1 Lipodystrophy syndromes. Facial lipoatrophy can be seen in patients with POEMS (polyneuropathy, organomegaly, endocrinopathy, monoclonal gammopathy, skin changes) syndrome and generalized lipoatrophy in children who have undergone an allogeneic hematopoietic stem cell transplant. AR, autosomal recessive; AD, autosomal dominant; *AGPAT2*, 1-acylglycerol-3-phosphate O-acyltransferase 2; *BSCL2*, Berardinelli–Seip congenital lipodystrophy 2 (Seipin) gene; CANDLE, chronic atypical neutrophilic dermatosis with lipodystrophy and elevated temperature; *CAV1*, caveolin 1 gene; *CAVIN1*, caveolae associated protein 1; *CIDEC*, cell death-inducing DFFA-like effector C; CVID, combined variable immunodeficiency; DM, diabetes mellitus; HDL, high-density lipoproteins; HIV, human immunodeficiency virus; LDL, low-density lipoproteins; IR, insulin resistance; *LIPE*, lipase, hormone-sensitive; PI, protease inhibitor; *PLIN*, perilipin 1; *PPARG*, peroxisome proliferator-activated receptor-γ; PTRF, polymerase I and transcript release factor; POMP, proteasome maturation protein; *PSMA*, proteasome subunit alpha; *PSMB*, proteasome subunit beta; *PSMG*, proteasome subunit gamma; SLE, systemic lupus erythematosus; TG, triglycerides; *ZMPSTE24*, gene that encodes a zinc metalloproteinase.

of metabolically active intra-abdominal adipose tissue but preservation of mechanical palmoplantar adipose tissue in patients with type 1 CGL. *BSCL2* has been found to also be highly expressed in the brain[18], which may account for the higher prevalence of intellectual disability in type 2 patients.

Familial Partial Lipodystrophy

Familial partial lipodystrophy (FPLD) is a heterogeneous group of autosomal dominantly, and rarely autosomal recessively, inherited disorders (see Table 101.1). The most prevalent subtype is FPLD2, which is due to mutations in *LMNA*[19]. *LMNA* encodes lamins A/C, with lamins belonging to the intermediate filament family of structural proteins that compose the nuclear lamina. *LMNA* mutations lead to a disruption in nuclear function, resulting in apoptosis and premature cell death of adipocytes, and they lead to alterations in the extracellular matrix of adipose tissue. There is also aberrant TGF-β signaling and this is associated with abnormal responses to metabolic requirements. Decreased plasma leptin and increased fasting plasma insulin and C-peptide levels are additional findings[20], as is premature senescence of vascular cells; the latter contributes to the observed cardiovascular complications[21]. Of note, *LMNA* mutations are responsible for a group of disorders known as laminopathies that includes premature aging syndromes (e.g. progeria), muscular dystrophies, cardiomyopathies, and one form of Charcot–Marie–Tooth neuropathy (see Tables 63.9 & 63.10). The clinical phenotype/syndrome is determined by the site and type of *LMNA* mutation(s)[22].

While the genetic basis of FPLD1 is unknown, FPLD3 results from heterozygous missense mutations of the gene that encodes peroxisome proliferator-activated receptor-γ (PPAR-γ)[23]. PPAR-γ plays an essential role in adipogenesis (see Fig. 101.14), but the entire pathogenesis remains unclear. Although this subtype has a milder phenotype than FPLD2, with a later age of onset and involvement confined to the distal

Downloaded for Anonymous User (n/a) at Egyptian Knowledge Bank from ClinicalKey.com by Elsevier on March 10, 2024. For personal use only. No other uses without permission. Copyright ©2024. Elsevier Inc. All rights reserved.

extremities, metabolic abnormalities are more severe, suggesting that *PPARG* mutations may have additional effects on metabolism.

In patients with FPLD4, heterozygous loss-of-function mutations have been described in the gene that encodes perilipin-1 (*PLIN1*)[24,25]. Perilipin is responsible for the formation, maturation, and function of lipid droplets within adipocytes. Lipoatrophy of the lower extremities is accompanied by marked hypertriglyceridemia and severe insulin resistance with type 2 diabetes.

To date, FPLD5 and FPLD6 are based on a single patient and three sets of siblings, respectively, and because of homozygous mutations (missense, nonsense) or deletions (FPLD5, FPLD6) and consanguinity (FPLD6), an autosomal recessive pattern is favored. The associated genes encode a member of the cell death-inducing DNA fragmentation factor-like effector family (*CIDEC*) that is thought to play a role in adipocyte apoptosis[26] and lipase E, hormone sensitive type (*LIPE*). While homozygous mutations in *CAV1* lead to congenital generalized lipodystrophy (see above), patients with FPLD7 are heterozygotic for *CAV1* mutations.

Partial lipodystrophy may also be seen in association with mandibuloacral dysplasia (MAD), an autosomal recessive syndrome associated with mutations in *LMNA* (type A), or with mutations in *ZMPSTE24*, which encodes a zinc metalloproteinase involved in post-translational proteolytic processing of prelamin A (type B)[27]. The latter has been associated with severe mandibuloacral dysplasia, premature aging, and generalized lipodystrophy.

Mesangiocapillary glomerulonephritis type 2 (MCGN II) has been reported in a case of partial lipodystrophy due to a mutation in *LMNA*, suggesting that partial lipodystrophy of both the sporadic and familial subtypes may predispose to this condition and the observed renal abnormalities and hypocomplementemia may be secondary to other factors associated with lipodystrophy[28].

Acquired Generalized Lipodystrophy (Lawrence Syndrome)

There is no known genetic defect. A third of patients have an antecedent autoimmune disease or viral or bacterial infection, but a causal relationship with the latter has not been established. The preceding panniculitis observed in 25% of patients (see Table 101.1)[29] and the frequent association of autoimmune disease imply immunologically mediated lipolysis. Autoantibodies against the adipocyte membrane have been reported in one patient with this condition[30], and anti-perilipin 1 antibodies in a second.[31] This autoimmune diathesis could also explain the high incidence of type 1 diabetes mellitus and reports of co-existing common variable immunodeficiency (CVID)[32].

Acquired Partial Lipodystrophy Syndrome (Barraquer–Simons Syndrome)

Acquired partial lipodystrophy syndrome occurs sporadically or may be autosomal dominant, with mutations in *LMNB2* detected in some patients[33]. Subcutaneous fat is often lost acutely after a viral illness. The exact pathogenesis is not known, but it may be related to adipsin, a protein produced by adipocytes which is identical to factor D (a component of the alternative complement pathway; see Ch. 60), as well as C3 nephritic factor (C3NeF), an IgG autoantibody against an alternative pathway enzyme. There is dysregulated activation of the alternative pathway, associated with C3NeF binding to the rate-limiting C3 convertase enzyme (C3bBb). This results in unopposed activation of the alternative complement pathway, excessive consumption of C3, and complement-dependent lysis of adipocytes.

Regional differences in factor D expression parallel the regional distribution of adipocyte loss in partial lipodystrophy, which may explain the cephalocaudal distribution of fat. Renal cells also express complement components, and a similar mechanism of complement-mediated injury may be responsible for the MCGN II seen in these patients[28].

Localized Lipoatrophy

The pathogenesis of localized lipoatrophy is heterogeneous. Circumscribed areas of lipoatrophy may follow inflammation from pyogenic abscesses, lobular panniculitides due to autoimmune connective tissue diseases (e.g. lupus erythematosus, dermatomyositis), or subcutaneous panniculitis-like T cell lymphoma.

Iatrogenic causes include traumatic and inflammatory responses to injected medications (Table 101.2). Anti-sense oligonucleotides (AONs), which modulate protein expression via hybridization with cellular RNA, represent the most recent addition to this list. One example of AONs is the experimental drug drisapersen[34].

In the case of insulin lipoatrophy, it may be induced by impurities and is significantly associated with the presence of anti-insulin antibodies[35]; mononuclear infiltrates near insulin injections suggest a localized immune response. Because repeated use of the same injection site increases the risk of lipoatrophy, the latter can be largely prevented by regular rotation of injection sites. Of note, lipoatrophy is fairly rare with the use of human insulin and insulin pump therapy. Lipoatrophy may also occur at injection sites of growth hormone and glatiramer acetate due to a direct lipolytic effect and panniculitis, respectively.

Lipoatrophia semicircularis may represent repetitive trauma or pressure-induced changes (Fig. 101.2), due to constant or intermittent pressure from leaning against the edges of furniture, basins and counters, or from tight-fitting clothing and elastic undergarments. Both resolution of the lesions when trauma is avoided and the occurrence of similar lesions in multiple employees in the same workplace provide support for microtrauma as the etiology[36]. Local hyperproduction of

INJECTED MEDICATIONS THAT CAN CAUSE LOCALIZED LIPOATROPHY
Most common
• Insulin*
• Non-human ≫ human, insulin analogues
• Rarely, can occur at distant sites
• Corticosteroids
Less common
• Antibiotics
• Benzathine penicillin†
• Amikacin
• Immunomodulatory drugs
• Glatiramer acetate (multiple sclerosis)
• Methotrexate†
• Vaccines
• Diphtheria–pertussis–tetanus vaccine
• Quadrivalent human papillomavirus vaccine
• Growth hormone
• Heparin
• Iron dextran
• Anti-sense oligonucleotides
• Anti-programmed cell death protein 1 (PD-1) antibodies
• Exogenous material
*Lipohypertrophy can also occur. †Including semicircular lipoatrophy.

Table 101.2 Injected medications that can cause localized lipoatrophy. Lipoatrophy can also be seen at sites of acupuncture.

Fig. 101.2 Lipoatrophia semicircularis (semicircular lipoatrophy). Bilateral slightly curved depressions on the anterolateral thighs. *Courtesy Diane Thaler, MD.*

Downloaded for Anonymous User (n/a) at Egyptian Knowledge Bank from ClinicalKey.com by Elsevier on March 10, 2024. For personal use only. No other uses without permission. Copyright ©2024. Elsevier Inc. All rights reserved.

Fig. 101.3 Localized lipoatrophy of the upper lateral calf due to pressure. A fairly common finding in women who cross their legs while seated. *Courtesy Jean L. Bolognia, MD.*

Fig. 101.4 Congenital generalized lipodystrophy syndrome (Berardinelli–Seip syndrome). A Lipoatrophy of the trunk leading to muscle definition. **B** Extensive acanthosis nigricans. *Courtesy Edward Cowen, MD.*

TNF by macrophages has been implicated[37]. Localized lipoatrophy of the upper and lateral calf due to pressure is commonly observed in women who cross their legs when seated (Fig. 101.3).

Up to 60% of *involutional lipoatrophy* (see below) may be associated with prior local injections, suggesting a trauma-related phenomenon[38]. Although lipophagocytizing macrophages seen by electron microscopy suggest an initial stimulation by injectable material, an active foreign body reaction is typically absent.

Lipodystrophia centrifugalis abdominalis infantilis is usually idiopathic, but has been reported to be associated with mechanical trauma or focal infection. Predominance of this condition in East Asia is notable and reports in twins and siblings point to the possibility of an HLA predisposition. In one patient with lipodystrophia centrifugalis abdominalis infantilis, positive immunohistochemical staining for Fas, Bcl-2 and p53, as well as terminal transferase-mediated dUTP nick end-labeling (TUNEL) in degenerating fatty tissue, suggested apoptosis as a possible factor[39].

CLINICAL FEATURES

Congenital Generalized Lipodystrophy (CGL)

CGL is rare, with an estimated prevalence of <1 case in 10 million[40]. As an autosomal recessive disorder, there is often consanguinity. All subtypes are characterized by generalized loss or absence of metabolically active subcutaneous fat from birth, resulting in a cadaveric facies and distinctive muscular-appearing body habitus (Fig. 101.4A). Anabolic features are evident in early childhood (Table 101.3). There is also a deficiency of bone marrow fat (types 1, 2) and visceral fat (types 1, 3, 4). Type 2 CGL also lacks mechanical fat, in addition to metabolically active fat.

The inability to store sufficient fat in the adipocytes results in the metabolic syndrome (see Table 53.5), which becomes more profound during puberty[40]. Diabetes mellitus is evident by adolescence, but hyperinsulinemia can be detected as early as infancy. Clitoromegaly is seen in women and may be associated with polycystic ovarian syndrome and infertility. Hepatosplenomegaly is typical and may be associated with umbilical herniation. Cutaneous findings (see Table 101.3) include acanthosis nigricans, which is noted by adolescence and may be extensive (Fig. 101.4B). Serious medical complications and metabolic derangements include cirrhosis from fatty liver, premature atherosclerosis, sequelae of diabetes, pancreatitis from hypertriglyceridemia, osteosclerosis[41], and a high mortality rate from hypertrophic cardiomyopathy[40]. Type 2 appears to be a more severe disorder that is associated with intellectual disability, hypertrophic cardiomyopathy, and a higher incidence of premature death while type 4 patients have arrhythmias from myocardial fibrofatty infiltration, esophageal dysmotility, and pyloric stenosis[16]. In one series of CGL, there was an ~35-year reduction in lifespan, with liver disease and infection as the most common causes of death[42].

Familial Partial Lipodystrophy

Familial partial lipodystrophy (FPLD) was first described by Dunnigan and Köbberling[42], who outlined the clinical characteristics of large Scottish and German pedigrees with familial syndromes of partial lipodystrophy. FPLD is classified based upon genetic mutations and clinical phenotype (see Table 101.1). This group of disorders differs from other forms of inherited lipodystrophy by a later onset (after puberty) and fat loss predominantly affecting the extremities, with sparing of the face[40]. FPLD is a rare disorder, with a prevalence of <1 in 15 million[40].

In FPLD2, a normal childhood is followed by a progressive, symmetric loss of subcutaneous fat; the latter uniformly involves the extremities and variably extends to the trunk (anterior > posterior). Compensatory accumulation of excess fat occurs and results in a fat head and neck, with a round face, as well as increased supraclavicular fat (see Fig. 101.1). Acromegalic facies with submental fullness ("double chin") is characteristic. As a result of the loss of fat in the limbs, there is an accentuation of subcutaneous veins and muscular prominence (Fig. 101.5). Although FPLD3 has milder clinical features and an onset after the second decade of life, the metabolic disturbances may be more severe[40].

Metabolic disturbances in FPLD are similar to those in the generalized lipodystrophy syndromes. Glucose intolerance, ranging from mild to severe, develops during young adulthood. Acute pancreatitis and hepatic steatosis and cirrhosis may occur, with complications from diabetes mellitus, atherosclerotic cardiovascular disease, or hypertrophic cardiomyopathy leading to premature death[40]. When compared to men, affected women have been reported to have more severe triglyceride elevations (chylomicronemia syndrome)[43]. Dermatologic manifestations include tuberous xanthomas, acanthosis nigricans and hirsutism, while gynecologic findings include menstrual irregularities, polycystic ovaries, and fat hypertrophy within the labia majora.

Familial partial lipodystrophy with mandibuloacral dysplasia is a rare variant of partial lipodystrophy characterized by mandibular and clavicular hypoplasia, short stature, a high-pitched voice, and ectodermal abnormalities of the skin, teeth, nails, and hair[27,40]. There are multiple craniofacial defects, including dental overcrowding and bird-like facies. Skeletal abnormalities include osteolysis of the clavicles, acro-osteolysis, delayed closure of cranial sutures, and joint contractures. Mottled hyperpigmentation, alopecia, atrophy of extremity skin, and nail dysplasia are the characteristic cutaneous findings. Less common clinical features include sensorineural hearing loss, delayed puberty, a high-arched palate, and cutaneous calcinosis. Features of the metabolic syndrome may be present (see Table 53.5).

Downloaded for Anonymous User (n/a) at Egyptian Knowledge Bank from ClinicalKey.com by Elsevier on March 10, 2024. For personal use only. No other uses without permission. Copyright ©2024. Elsevier Inc. All rights reserved.

FEATURES OF CONGENITAL GENERALIZED LIPODYSTROPHY
Lipodystrophic features
• Lack of fat in the buccal region, resulting in a cadaveric facies • MRI studies show near total absence of subcutaneous fat and other metabolically active adipose tissues • Preservation of fat deposits in "mechanical" sites (types 1, 3, 4): orbit, palms, soles, tongue, breasts, vulva, and in periarticular and epidural regions • Muscular body habitus due to the extreme paucity of subcutaneous fat
Anabolic features
• Muscular hypertrophy with prominent superficial veins • Acromegalic facial and acral features • Voracious appetite • Increased basal metabolic rate • Heat intolerance • Accelerated growth with a normal to slightly increased adult height • Advanced bone and dental age • Osteosclerotic and lytic skeletal changes • Masculine features in females (clitoromegaly rare) • Enlarged genitalia (usually limited to infancy and childhood)
Metabolic disturbances
• Insulin resistance and severe fasting or postprandial hyperinsulinemia from early infancy • Insulin levels may decrease after several years, due to exhaustion of pancreatic β cells • Very insulin-resistant diabetes mellitus: noted at puberty with growth cessation • Impaired glucose tolerance is noted around age 8–10 years • Hypertriglyceridemia and sequelae (chylomicronemia, pancreatitis) • Hyperlipidemia accelerates at puberty (with growth cessation) • Low HDL-cholesterol levels (accurate assessment may be hindered by the increased TGs) • Low plasma leptin levels, corresponding to decreased body fat • Osteosclerosis (increased density)
Dermatologic manifestations
• Acanthosis nigricans, often early onset and widespread • Hypertrichosis, including increased (often curly) scalp hair at birth • Hyperhidrosis • Coarse skin on the upper body • Hyperkeratotic epidermal papillomatosis (may represent an exaggerated form of acanthosis nigricans) • Xanthomas
Gynecologic disturbances
• Oligomenorrhea • Polycystic ovaries • Infertility (females)
Organomegaly and organ dysfunction
• Hypertrophic cardiomyopathy (often fatal) • Fatty liver, hepatomegaly, cirrhosis, liver failure • Organomegaly: tonsils and adenoids, lymph nodes, spleen, kidneys, adrenals, pancreas, ovaries • Central nervous system abnormalities: hypothalamic–pituitary dysfunction, ventricular dilation, below average intelligence, ± mild mental retardation • Proteinuric nephropathy

Table 101.3 Features of congenital generalized lipodystrophy.[2,33] HDL, high-density lipoprotein; MRI, magnetic resonance imaging; TG, triglyceride.

Proteasome-Associated Autoinflammatory Syndromes

To date, five types of proteasome-associated autoinflammatory syndrome (PRAAS) have been identified and are due to mutations in seven genes that encode proteasome-associated proteins (see Table 45.7). PRAAS1 has also been referred to as CANDLE (chronic atypical neutrophilic dermatosis with lipodystrophy and elevated temperature) syndrome[44] and Nakajo–Nishimura syndrome[45]. In addition to recurrent fevers, annular violaceous plaques, eyelid erythema, and pernio-like lesions that begin during infancy or early childhood[46], patients can develop panniculitis-induced lipodystrophy. Partial (e.g. PRAAS1) or generalized (e.g. PRAAS4) lipoatrophy has been described. In biopsy specimens of nodules, a dense dermal infiltrate of atypical myeloid cells that resembles leukemia cutis or "histiocytoid" Sweet syndrome is seen, along with mature neutrophils. Treatment options include JAK inhibitors, corticosteroids, and methotrexate.

Fig. 101.5 Lipoatrophy of the lower extremities, leading to muscular prominence. *Courtesy William D. James, MD.*

Recurrent lipoatrophic panniculitis of children

In this syndrome, painful subcutaneous nodules are accompanied by fever, malaise, abdominal pain, and arthralgias[47]. Localized lipoatrophy then develops at the sites of nodules. Histopathologically, there is a lobular panniculitis with a mixed infiltrate composed of neutrophils, lymphocytes, macrophages, and mononuclear myeloid cells. Methotrexate and/or corticosteroids led to clinical improvement. The authors proposed that this constellation may represent an autoinflammatory disease. Of note, whole genome sequencing did not detect a form of PRAAS (see previous section)[47].

Acquired Generalized Lipodystrophy (Lawrence Syndrome)

To date, ~80 cases of acquired generalized lipodystrophy (AGL) have been reported in the English literature. New diagnostic criteria for AGL have been proposed, as well as a sub-classification into three subtypes (Table 101.4).

In approximately one-third to one-half of patients, there is a preceding systemic illness, in particular, a viral or bacterial infection or an autoimmune disorder (e.g. a connective tissue disease, thyroiditis)[40]. The rare patients who also have CVID can have recurrent infections (see Ch. 60). Drug-induced lipodystrophy, e.g. due to immune checkpoint inhibitors, needs to be excluded (see below).

Clinical features of AGL are similar to those of the congenital variant, but are of later onset and milder. The lipoatrophy typically does not become apparent until childhood or adolescence and rarely develops during adulthood. This disorder is three times as common in women. Large areas of the face, trunk, and extremities have fat loss (Fig. 101.6), and the palms and soles may even be involved. Loss of acral subcutaneous fat as well as perinephric and intra-abdominal fat can be documented by MRI scans. However, bone marrow fat is preserved, and this feature can be helpful in differentiating AGL from CGL types 1 and 2.

Tender subcutaneous nodules of panniculitis may precede the lipoatrophy in the type 1 variant and there may be an overlap in the

Downloaded for Anonymous User (n/a) at Egyptian Knowledge Bank from ClinicalKey.com by Elsevier on March 10, 2024. For personal use only. No other uses without permission. Copyright ©2024. Elsevier Inc. All rights reserved.

panniculitic and autoimmune subtypes. Progression can occur rapidly or over an extended period. When the lipodystrophy becomes generalized, metabolic abnormalities begin to manifest. Although the latter are less severe in AGL than in CGL, the period between the appearance of lipoatrophy and development of frank diabetes (~4 years) is shorter in AGL[40]. The extent of fat loss mirrors the severity of insulin resistance and hypertriglyceridemia.

Compared to the autoimmune and idiopathic types of AGL, the panniculitic variant may have less severe fat loss and a lower prevalence of diabetes and hypertriglyceridemia (see Table 101.4)[30]. In addition, the associated anabolic features are variable and less prominent and its severity is less striking when the condition starts in later childhood or adulthood.

In AGL, hepatic steatosis is commonly present in affected children, leading to a higher incidence of hepatomegaly, cirrhosis, and liver-related mortality than in CGL. Gynecologic abnormalities include true or pseudo-clitoromegaly (the latter due to fat loss), polycystic ovarian syndrome, and menstrual irregularities. Premature coronary artery disease and carotid or peripheral arterial disease may occasionally be seen. Renal and central nervous system abnormalities are usually absent.

ACQUIRED GENERALIZED LIPODYSTROPHY: PROPOSED DIAGNOSTIC CRITERIA AND SUBTYPES
Essential criterion
Selective loss of fat involving large regions of the body beginning during childhood or adolescence
Supportive criteria

• Clinical
  • Loss of subcutaneous fat from the palms and soles
  • Acanthosis nigricans
  • Hepatosplenomegaly
  • Panniculitis prior to onset (by clinical history and/or histologic confirmation; see below)
  • Associated autoimmune diseases (see below)
• Laboratory
  • Diabetes mellitus or impaired glucose tolerance
  • Severe hyperinsulinemia (fasting and/or postprandial)
  • Increased serum triglyceride and/or decreased HDL-cholesterol levels
  • Reduced serum leptin and/or adiponectin levels
  • Anthropometric or MRI evidence of large regions of fat loss
  • MRI evidence of preserved bone marrow fat

Subtypes

• Panniculitic variant (type 1)
  • Panniculitis precedes the onset of lipoatrophy, which may be noted in the center of expanding annular lesions or at distant sites
  • Mean age of onset is 7 years; slight female predominance (~1.5-fold)
  • Associated symptoms include low-grade fever, malaise, arthralgias, and abdominal pain
  • May be associated with autoimmune diseases (see below)
  • Relatively mild metabolic derangements and leptin abnormalities
  • Histopathologic evaluation reveals a mostly lobular lymphohistiocytic subcutaneous infiltrate ± granulomatous foci
• Autoimmune variant (type 2)
  • Concurrent or prior autoimmune disease without preceding panniculitis; associated with juvenile dermatomyositis, Sjögren syndrome, juvenile idiopathic arthritis, vitiligo, chronic urticaria/angioedema, and autoimmune thyroiditis, hepatitis or hemolytic anemia
  • Mean age of onset is 15 years; female predominance (~3-fold)
  • Hepatomegaly is invariably present; hypertriglyceridemia and diabetes mellitus occur in most patients
  • Laboratory abnormalities may be observed without clinical evidence of autoimmune disease, including antinuclear, anti-smooth muscle, anti-glomerular basement membrane, anti-salivary duct, antimitochondrial, and anti-adrenal/ovary/placenta/testis antibodies
• Idiopathic (type 3)
  • No evidence of panniculitis or autoimmune disease
  • Mean age of onset is 20 years (range, <2–60 years); female predominance (~3-fold)

Table 101.4 Acquired generalized lipodystrophy: proposed diagnostic criteria and subtypes. *Adapted from reference 29.*

Dermatologic features of AGL, in addition to panniculitis and lipoatrophic areas, include acanthosis nigricans, localized or generalized hyperpigmentation, eruptive xanthomas, telangiectasias, mild palmar/plantar keratoderma, and hair abnormalities, including mild hirsutism, curly hair, and occasional alopecia. The acanthosis nigricans begins in childhood and involves the neck, axillae, groin, umbilicus, and nipples. Associated autoimmune diseases include juvenile dermatomyositis, Sjögren syndrome, and vitiligo. In addition, patients may have chronic urticaria and angioedema (see Table 101.4).

Acquired Partial Lipodystrophy (Barraquer–Simons Syndrome)

Acquired partial lipodystrophy, also known as progressive lipodystrophy or cephalothoracic lipodystrophy, is the second most common type of non-localized lipodystrophy, after HIV/ART-related lipodystrophy. It has been reported worldwide, with more than 250 patients described in the literature[40,48].

Three phenotypic subtypes have been noted: (1) fat loss in the upper half of the body; (2) fat loss in the upper half of the body, with hypertrophy of adipose tissue in the lower half; and (3) hemi-lipodystrophy, where one half of the face or body is affected.

Lipodystrophy begins during childhood or pre-puberty (median age at diagnosis is 8–10 years) and sometimes follows a viral illness. It is characterized by an insidious onset, with symmetric and progressive loss of subcutaneous fat in a cephalocaudal direction (Fig. 101.7). Extension of the lipoatrophy usually takes place over a 1- to 2-year period, but can occur over many years. Physical findings may be apparent by adolescence, although the onset may be delayed until 40 years of age. Women are affected three times more often than men.

The face is usually affected first, with sunken eyes due to loss of retro-orbital and periorbital fat. This is accentuated by concurrent loss of buccal and temporal fat, resulting in a progeria-like or cadaveric appearance (Fig. 101.8). The hips and legs tend to be spared, and often demonstrate fat hypertrophy, especially in women. Growth delay or stunted growth is not characteristic of this disorder.

MCGN II with nephritic syndrome, seen in approximately one-fifth of patients, may occur many years, usually about eight, after the onset of lipodystrophy. Almost all patients with acquired partial lipodystrophy have low levels of C3 in addition to circulating C3 nephritic factor (C3NeF), composed of polyclonal IgG[28]. This leads to unopposed activation of the alternative complement pathway (see above) and C3NeF-induced lysis of adipocytes. The low C3 level also predisposes

Fig. 101.6 Acquired generalized lipodystrophy. There is loss of subcutaneous fat, resulting in a muscular appearance of the legs and accentuation of the tendons. *Courtesy Jacqueline Junkins-Hopkins, MD.*

Downloaded for Anonymous User (n/a) at Egyptian Knowledge Bank from ClinicalKey.com by Elsevier on March 10, 2024. For personal use only. No other uses without permission. Copyright ©2024. Elsevier Inc. All rights reserved.

Fig. 101.7 Acquired partial lipodystrophy syndrome in a patient with nephritic factor and renal disease. Lipoatrophic features are most prominent on the face. There is obvious loss of buccal fat. The patient also had axillary acanthosis nigricans. *Courtesy Kenneth E. Greer, MD.*

Fig. 101.8 Acquired partial lipodystrophy syndrome in a patient with Sjögren syndrome. Lipoatrophy of the face with sunken eyes and loss of temporal and buccal fat pads. The facial pigmentation is related to lichen planus. *Courtesy Priya Sen, MD.*

these patients to recurrent *Neisseria meningitidis* infections and repeat vaccinations may be required.

Other autoimmune associations include systemic lupus erythematosus, juvenile dermatomyositis, systemic sclerosis, Sjögren syndrome, pernicious anemia, hypothyroidism, celiac disease, dermatitis herpetiformis, temporal arteritis, and small vessel vasculitis.

Metabolic syndrome is less common in APL than in other lipodystrophies, but acanthosis nigricans, menstrual abnormalities, hirsutism, insulin resistance, type 2 diabetes mellitus, and hyperlipidemia may be seen.

Localized Lipoatrophy

Localized lipoatrophy presents as one or multiple depressed areas, usually on the proximal extremities, ranging from under a few centimeters to greater than 20 cm in diameter. *Drug-induced lipoatrophy* is most commonly due to injections of corticosteroids and non-human insulin (see Table 101.2); it may be accompanied by local lipohypertrophy. Of note, multifocal lipoatrophy due to intravenous corticosteroid use has been described and insulin injection-related lipoatrophy can appear at distant sites.

Fig. 101.9 Localized lipoatrophy secondary to lupus panniculitis. A An area of depression on the cheek due to burnt-out lupus panniculitis; note the dyspigmentation and scarring from an overlapping lesion of discoid lupus erythematosus. **B** Circular depressions on the upper arm, a common location for lupus panniculitis. *A, Courtesy National Skin Centre, Singapore.*

Involutional lipoatrophy is an idiopathic lipoatrophy characterized clinically by non-inflammatory focal loss of fat. Based on reported cases, there is a strong female predominance. Focal oval areas of lipoatrophy, 2 to 8 cm in diameter, occur predominantly on the buttocks and proximal extremities, especially the upper arm, corresponding to locations frequently used as injection sites. Although it is estimated that up to 60% of cases of involutional lipoatrophy may be associated with prior local injections (see above), this type of lipoatrophy may occur without prior injections.

Atrophic connective tissue panniculitis is rare, and it often occurs on the upper or lower extremities. In "pure" cases of this condition, there is no prior clinical inflammation although there is evidence histologically of lymphocytic panniculitis. In other patients, the lipoatrophy may be the direct result of clinical panniculitis. The latter is common on the head and neck or proximal extremities if associated with lupus panniculitis (also referred to as lupus profundus; Fig. 101.9). Other associated autoimmune diseases include dermatomyositis, thyroiditis, juvenile idiopathic arthritis, vitiligo, and insulin-dependent diabetes mellitus.

Lipoatrophia semicircularis (semicircular lipoatrophy) has been reported primarily in women in their 20s to 30s and rarely in children. It presents as symmetric, asymptomatic, 4–8 cm curvilinear horizontal depressions on the anterolateral thighs (see Fig. 101.2). Infrequent presentations include two or three parallel depressions, a unilateral distribution, or symptoms of cramps, pain after sports, heavy legs, or a burning sensation. The lesions usually appear over a few weeks and spontaneously resolve between 9 months to 4 years. The lipoatrophy may recur. MRI can assist in differentiating this from an inflammatory panniculitis.

Annular lipoatrophy presents with a deep, persistent, pseudosclerotic band approximately 9–11 cm in length that encircles the arm or ankle[49]. More extensive lesions have been reported that were 14–16 cm in length. It may be preceded by tenderness and swelling of the limb, or be associated with discomfort and arthritis. This entity may represent a variant or end-stage presentation of atrophic connective tissue disease panniculitis. Thus, there may be patients with associated autoimmune diatheses.

Downloaded for Anonymous User (n/a) at Egyptian Knowledge Bank from ClinicalKey.com by Elsevier on March 10, 2024. For personal use only. No other uses without permission. Copyright ©2024. Elsevier Inc. All rights reserved.

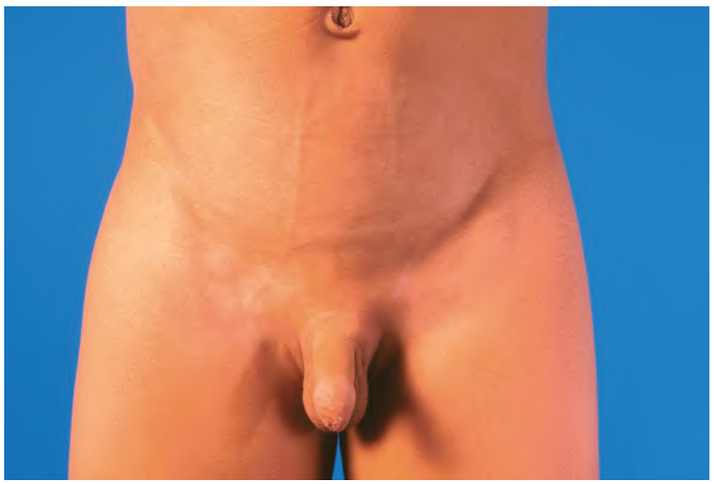

Fig. 101.10 Lipodystrophia centrifugalis abdominalis infantilis (centrifugal lipodystrophy). A 5-year-old Malay boy with a two-year history of progressive lipoatrophy involving the groin bilaterally and the lower abdomen. The veins in the involved area are readily visible. *Courtesy National Skin Centre, Singapore.*

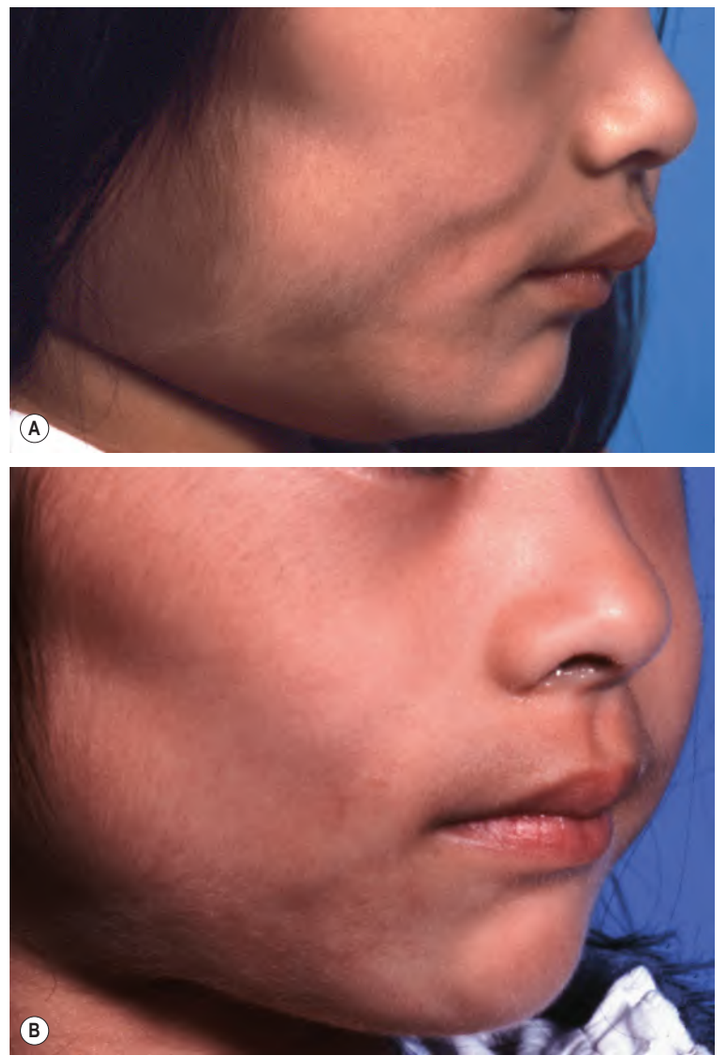

Fig. 101.11 Lipodystrophia centrifugalis infantilis (centrifugal lipodystrophy) of the face. A A 2-year-old girl with a serpentine violaceous band involving the cheek in association with lipoatrophy. **B** The same child two years later, with spontaneous resolution. The most common location for lipodystrophia centrifugalis infantilis is the abdomen (see Fig. 101.10). *Courtesy National Skin Centre, Singapore.*

Lipodystrophia centrifugalis abdominalis infantilis (centrifugal lipodystrophy) has largely been reported from East Asia, with most patients of Japanese, Korean, or Chinese origin[50]. Onset is usually before 3 years of age, with >90% of patients presenting by age 5 years. In Koreans, there is a four-fold female predominance[51]. Although lipodystrophia centrifugalis abdominalis infantilis affects primarily Asian children, it may occasionally occur in Caucasians and in adults.

Clinically, a well-demarcated area of lipoatrophy with a periphery of erythema and scale is seen on the abdomen or elsewhere on the trunk, often with associated regional lymphadenopathy. The lipoatrophy begins on the lower abdomen or in the groin region (and may include the genitalia) in about 80% of patients, and in the axillary region in about 20% of patients; it spreads onto the abdomen or chest, respectively, in a centrifugal fashion (Fig. 101.10). The underlying blood vessels become visible and ulceration may occur within the depressed areas. Contrary to its original name, this condition can affect non-abdominal sites such as the face, neck, and lumbosacral region (Fig. 101.11A), and it is not limited to infants. The lesions may progress slowly over several years, then often cease enlarging by 13 years of age[49]. Although there is no specific therapy, >60% of patients spontaneously improve (Fig. 101.11B).

Progressive hemifacial atrophy (Parry–Romberg syndrome) is considered to be a form of severe linear morphea (see Ch. 44). In addition to lipoatrophy, there may be atrophy of the underlying muscle and bone as well as the potential for ophthalmologic, dental, and neurologic involvement. An association with *Borrelia burgdorferi* infection has been reported in Europe.

Non-progressive late-onset linear hemifacial lipoatrophy occurs on the malar cheek, primarily in elderly individuals.

Inflammatory reactions due to material injected for cosmetic purposes or from self-inflicted injections of foreign material can lead to lipoatrophy which may be associated with scarring and dyschromia.

Lipohypertrophy

Lipohypertrophy remains a frequent complication of insulin therapy, irrespective of the insulin source and mode of administration[52]. As with insulin lipoatrophy, anti-insulin antibodies are associated with lipohypertrophy in children and adolescents with type 1 diabetes. The clinical consequence is that injection of insulin into a site of lipohypertrophy, while painless, may lead to erratic absorption of the insulin with poor glycemic control and rebound phenomenon[52]. Of note, insulin-induced nodular amyloidosis may have a clinical appearance similar to lipohypertrophy.

Injection of pegvisomant, a growth hormone receptor antagonist used to treat acromegaly, is another cause of lipohypertrophy (Table 101.5).

CAUSES OF LIPOHYPERTROPHY
• **Insulin therapy –** risk factors include duration of therapy, frequent injections, failure to rotate sites of injections, and poor injection technique
• **Pegvisomant (growth hormone receptor antagonist) injections***
• **Growth hormone injections**
• **Excess corticosteroids** – includes Cushing disease (excessive ACTH production by the pituitary gland) and Cushing syndrome (iatrogenic, adrenal tumors, nodular adrenal hyperplasia, ectopic ACTH production)
• **HIV/ART-associated** – risk factors include extended exposure to nucleoside reverse transcriptase inhibitors, exposure to protease inhibitors, age ≥40 years, longer duration of therapy, higher body mass index before onset of therapy, and presence of metabolic derangements (elevated serum triglyceride and insulin levels; depressed serum testosterone levels)
• **Lipodystrophy syndromes** – familial partial lipodystrophy (neck and face), acquired partial lipodystrophy (hips and lower extremities)
*Used to treat acromegaly.

Table 101.5 Causes of lipohypertrophy.

PATHOLOGY

Generally speaking, the histologic picture of the various lipodystrophy syndromes (see Table 101.1) is non-inflammatory. In *generalized lipodystrophy*, there is complete or near-complete loss of subcutaneous fat, with the dermis and fascia in direct apposition. Less often,

Downloaded for Anonymous User (n/a) at Egyptian Knowledge Bank from ClinicalKey.com by Elsevier on March 10, 2024. For personal use only. No other uses without permission. Copyright ©2024. Elsevier Inc. All rights reserved.

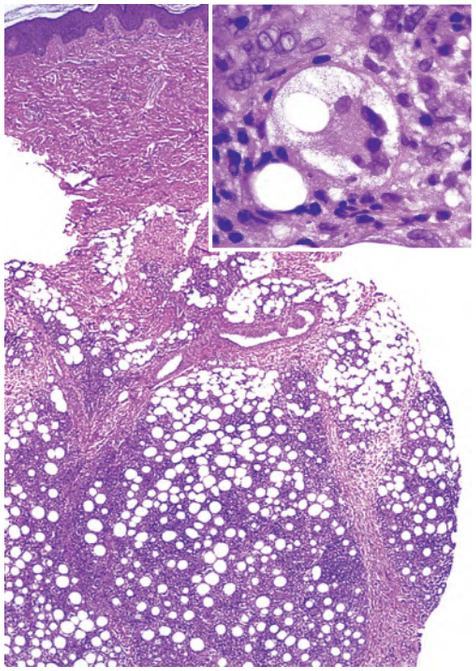

Fig. 101.12 Histopathologic features of the preceding panniculitis in type 1 acquired generalized lipodystrophy. Lobular panniculitis with infiltrate of lymphocytes, histiocytes, multinucleated giant cells, and lipophages. There is also cytoplasmic vacuolization of the fat cells (inset). See Table 101.4 for three types. *Courtesy Jacqueline Junkins-Hopkins, MD.*

biopsy specimens appear to have no overt abnormalities, except for an increased amount of collagen, which has replaced the subcutaneous fat. In contrast, biopsies of *acquired generalized lipodystrophy*, in particular type 1, may show a lobular panniculitis (Fig. 101.12; see Table 101.4).

In *acquired generalized lipodystrophy* and areas of lipoatrophy in some forms of *partial lipodystrophy*, two histologic patterns have been recognized: (1) non-inflammatory with involutional changes of the fat; and (2) inflammatory in the form of a lobular panniculitis with lymphocytes, lipophages, and plasma cells[53]. Whether these two patterns are stage-related remains to be clarified, as even in patients without panniculitis clinically, biopsies of early lesions may show inflammation, but it is usually mild.

Involutional changes of the subcutaneous fat are characterized by small fat lobules with a reduction in the size and number of adipocytes (Fig. 101.13). *Involutional lipoatrophy* can be further divided into two histologic subtypes[38]. In the first type, the lobules may be composed of faintly acidophilic, small fat cells that retract from one another as well as the surrounding connective tissue, leading to an appearance similar to embryonic fat; the lobules often have an eosinophilic appearance. These histologic findings are more prominent at the periphery of the clinically depressed area, with tiny acidophilic fat cells present more centrally. Inflammation is absent to sparsely mononuclear. The second type, with indistinguishable clinical features, shows small atrophic adipocytes with a normal fat cell membrane surrounded by prominent vasculature. At scanning magnification, the lobules are collapsed (with an orientation parallel to the skin surface) and surrounded by numerous capillaries. Acid mucopolysaccharide deposition within the fat lobules and fibrosis of the septae may be seen, as well as occasionally lipomembranous changes.

Although birefringent, non-crystalline material may occasionally be observed, foreign body giant cells and lipophages are typically absent in both subtypes of involutional lipoatrophy. $CD68^+$ macrophages can be demonstrated with immunohistochemical staining. Ultrastructural studies have shown that these are lysosomally active macrophages adjacent to lipocytes and likely containing degenerated lipid remnants[38]. In *localized lipodystrophy*, a loss of fatty tissue is seen, along with a variable degree of fibrosis. There is usually no inflammatory infiltrate, although panniculitis has been reported in a few cases. Deposits of immunoreactants can be seen within blood vessel walls or the basement membrane, particularly in the inflammatory type.

Histologically, well-developed areas of *lipodystrophia centrifugalis abdominalis infantilis* show a diminution of subcutaneous fat with scant or absent inflammation. The erythematous rim tends to correspond to a moderate or marked lymphohistiocytic infiltrate in the subcutaneous fat; a deep dermal and peri-eccrine lymphocytic infiltrate

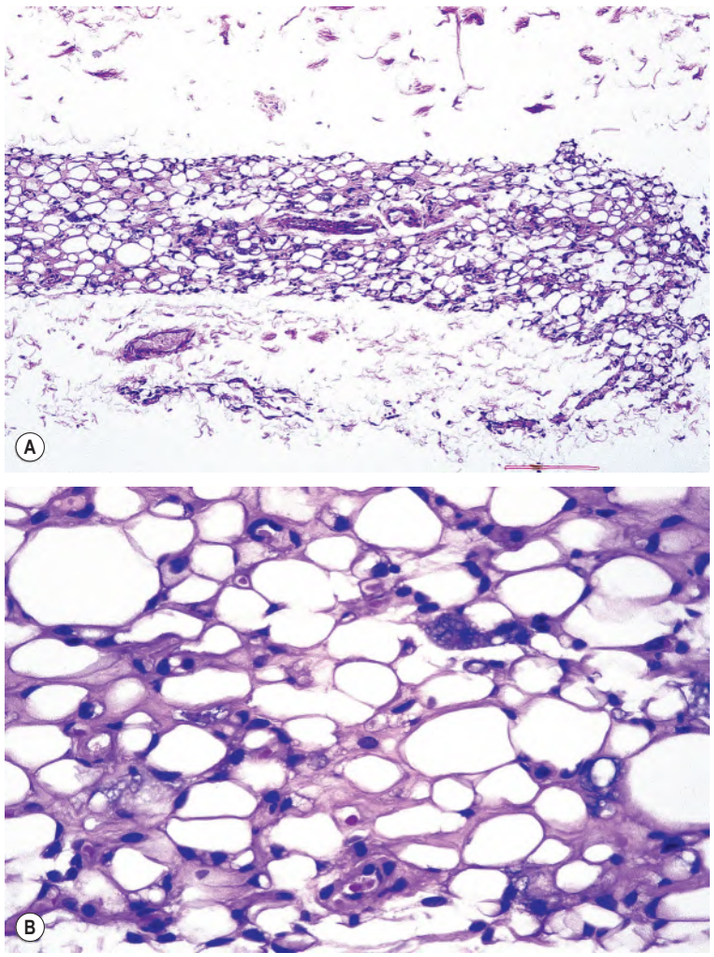

Fig. 101.13 Histopathologic features of involutional lipoatrophy secondary to corticosteroid injection. A There is marked diminution and collapse of the fat lobules, without inflammation. **B** Higher power demonstrates decreased size of fat cells with eosinophilic thickened cell walls with a hyalinized and mucinous stroma. *Courtesy Jacqueline Junkins-Hopkins, MD.*

is an uncommon finding. There may be fibrosis and thickening of the septae within the subcutis. The few adipocytes that are present may have myxoid changes.

Other localized variants such as *lipoatrophia semicircularis* (semicircular lipoatrophy) and *drug-induced lipoatrophy* usually show a loss of fatty tissue and replacement by collagen, with no features of panniculitis. There are often scattered lipophages. However, at sites of glatiramer acetate injections, panniculitis that resembles lupus profundus histologically can be seen. Lastly, HIV/ART-associated lipodystrophy resembles the non-inflammatory pattern of lipodystrophy.

DIFFERENTIAL DIAGNOSIS

There are a variety of other complex syndromes that present with lipoatrophy along with a number of other physical and systemic features (see below). A detailed discussion of these syndromes is beyond the scope of this chapter.

The excessive fat accumulation seen in patients with FPLD2 and HIV/ART-associated lipodystrophy could be confused with Cushing syndrome and obesity. Acromegaly can have overlapping features with generalized lipodystrophy.

In an infant with generalized lipodystrophy, the following conditions should also be considered:

- *Leprechaunism* (Donohue syndrome) is included in some lipodystrophy classifications, as the patients present with generalized lipodystrophy, severe insulin resistance, acanthosis nigricans, and hirsutism. In contrast to CGL, these patients have a distinct elfin facies, severe intrauterine growth retardation, prominent nipples, cutis laxa, mutations in the insulin receptor gene, and death during infancy.

Downloaded for Anonymous User (n/a) at Egyptian Knowledge Bank from ClinicalKey.com by Elsevier on March 10, 2024. For personal use only. No other uses without permission. Copyright ©2024. Elsevier Inc. All rights reserved.

- *SHORT syndrome* (*s*hort stature, *h*yperextensible joints or *h*ernia, *o*cular depression, *R*ieger anomaly [iridocorneal mesodermal dysgenesis], and *t*eething delay) is also included in some lipodystrophy classifications, as there is congenital lipoatrophy of the face and upper body. This condition is distinguished by the above-outlined abnormalities, intrauterine growth retardation, delayed bone age, mutations in *PIK3R1*, and a dysmorphic facies, which includes a triangular shape, micrognathia, deep-set eyes, and anteverted ears. Metabolic abnormalities are rare to absent.
- *Progeria-type syndromes* are characterized by limb lipoatrophy, cardiovascular disease and diabetes, but they are accompanied by muscle wasting, sclerodermatous changes, cataracts, and other signs of premature aging. Some of the progeric syndromes have *LMNA* mutations similar to those associated with FPLD, and may be considered as part of a broader group of disorders termed laminopathies (see Table 63.10).
- In *Cockayne syndrome*, lipoatrophic changes are accompanied by growth delay, retinal abnormalities, photosensitivity, and defects in DNA repair (see Chs. 63 & 87).
- *AREDYLD syndrome*: congenital generalized lipoatrophic diabetes is associated with an acrorenal field defect and ectodermal dysplasia.

In the case of partial lipodystrophy, there was a report of diffuse, symmetrical lipoatrophy of the lower extremities following extensive inflammation due to lobular panniculitis[54]. Neither underlying autoimmune diseases nor exogenous causes were identified.

Localized lipodystrophies should be differentiated from initial phases of progressive lipodystrophy, morphea, lupus panniculitis, and atrophoderma of Pasini and Pierini. Although there is overlap amongst the various types of localized lipodystrophy, the distribution and morphology combined with a history of injections, the presence clinically or histologically of panniculitis, and associated autoimmune disorders may aid in the diagnosis.

Poland syndrome is a rare congenital disorder consisting of unilateral partial or total absence of a breast and/or pectoralis major muscle plus ipsilateral symbrachydactyly, which may simulate lipoatrophy. Lipohypoplasia, as is seen in disorders such as Proteus syndrome, can also mimic lipoatrophy.

Lastly, whole-body MRI has been shown to assist in differentiating the various subtypes of lipodystrophies, based upon the amount and extent of residual adipose tissue and the absence or preservation of marrow fat[55]. This information, in combination with the clinical phenotype and especially genetic testing, improves diagnostic accuracy and prognostication.

TREATMENT

Therapeutic interventions for lipodystrophy syndromes focus on three aspects: (1) cosmetic concerns; (2) metabolic derangements; and (3) systemic associations[56]. For volume loss due to lipoatrophy, soft tissue fillers and autologous fat transplantation can be helpful, albeit temporarily[57,58]. Solid synthetic volumetric midfacial implants, constructed using computer-aided design and manufacturing technology, may offer a more durable correction of the defects[59]. A conservative approach can be undertaken when spontaneous improvement may occur as in pressure-induced or traumatic lipoatrophy. For lipohypertrophy, liposuction and lipectomy represent moderately effective treatments[60]. Switching to purified human insulin may improve lipoatrophy at sites of insulin injections, but it may require 1 to 3 years[52].

The treatment of metabolic abnormalities requires input from dieticians and endocrinologists[56]. Several medications are used to address insulin resistance and glucose control including thiazolidinediones, metformin, sulfonylureas, dipeptidyl peptidase 4 inhibitors ("gliptins"), glucagon-like peptide 1 agonists, sodium-glucose cotransporter-2 inhibitors (gliflozins), and insulin[56]. Treatment of hypertriglyceridemia includes diet, fibrates, omega-3 fatty acids, niacin, and statins[56,61]. For refractory metabolic disease, bariatric surgery can be considered[62].

Of note, recombinant methionyl human leptin (metreleptin) is FDA-approved for the treatment of congenital or acquired *generalized* lipodystrophy. Metreleptin binds to hypothalamic leptin receptors, leading to decreased appetite and increased insulin sensitivity. Marked improvements in glycemic control, hyperlipidemia, hepatic steatosis, and diabetic complications such as proteinuria have been reported[63]. Metreleptin is generally well tolerated, with sustained effects as long as neutralizing anti-metreleptin antibodies do not develop. There is also a black box warning regarding risk of lymphoma. It has also been shown to be an effective steroid-sparing therapy for the acquired generalized lipodystrophy that can follow allogeneic hematopoietic stem cell transplantation[64].

In acquired partial lipodystrophy, longitudinal evaluation will allow identification of associated autoimmune connective tissue diseases (e.g. lupus, dermatomyositis), thyroid disease, or renal disease that requires treatment. Such treatment may halt the progression of the lipodystrophy. If proteinuria, a low serum C3, and C3 nephritic factor (C3NeF) are detected, a renal biopsy to exclude MCGN II may be required. Encouraging results following the use of IVIg have been reported, presumably due to the IVIg containing neutralizing antibodies against C3NeF[65]. When no secondary cause is found, treatment is limited.

Additional potential therapies include volanesorsen, an antisense oligonucleotide that binds to apoC-III mRNA and is EMA-approved for familial chylomicronemia syndrome but not FDA-approved because of the risk of thrombocytopenia. Both evinacumab, a human angiopoietin-like 3 (ANGPTL3) blocking antibody that is currently FDA-approved for homozygous familial hypercholesterolemia, and gemcabene calcium, a dialkyl ether dicarboxylic acid which has orphan drug designation for the same indication, have also shown efficacy in patients with severe hypertriglyceridemia[56]. Setmelanotide, a melanocortin-4 receptor agonist, is FDA-approved for obesity due to deficiencies of proopiomelanocortin (POMC), proprotein convertase subtilisin/kexin type 1 (PCSK1), or leptin receptor (LEPR) and may reduce triglyceride levels.

ACQUIRED LIPODYSTROPHY DUE TO OTHER CAUSES

Medications

HIV/ART-associated lipodystrophy

Worldwide, HIV/ART-associated lipodystrophy is still the most common form of non-localized lipodystrophy. Fortunately, its incidence has fallen significantly with the advent of new ARTs and increased awareness of its association with protease inhibitors (PI) and nucleoside analogue reverse transcriptase inhibitors (NRTIs) such as stavudine and didanosine. There are several proposed mechanisms to explain this particular type of lipodystrophy (Fig. 101.14; Table 101.6) and they include:

- impaired pre-adipocyte differentiation and increased adipocyte apoptosis[66,67]
- impaired insulin-stimulated lipogenesis and increased lipolysis[66], leading to decreased adipocyte size
- mitochondrial toxicity[68].

HIV/ART-associated lipodystrophy reflects an interplay of several factors including the type of ART administered, direct effects of HIV proteins, and other host factors such as age and severity of HIV infection. The key contributor is extended use of higher-risk ARTs, in particular the older-generation NRTIs (e.g. stavudine, didanosine), early PIs (e.g. indinavir, full-dose ritonavir), and raltegravir (an integrase strand transfer inhibitor [INSTI])[69]. Host risk factors include an age >40 years and more severe HIV infection (e.g. $CD4^+$ count <200/mcl, higher nadir viral load) at the onset of therapy[70,71]. Baseline subcutaneous body fat composition prior to ART also plays a role, with a higher risk of lipoatrophy in individuals with lower body fat and a higher risk of lipohypertrophy in those with higher body fat[70,71].

The clinical findings in HIV/ART-associated lipodystrophy include: (1) irreversible lipoatrophy of peripheral sites, primarily the face, extremities, heel pads, and buttocks (Fig. 101.15 & 101.16); (2) central lipohypertrophy or adipose tissue accumulation, especially dorsocervical, supraclavicular and mammary, as well as intra-abdominal and visceral (e.g. liver); and (3) development of metabolic abnormalities. In cross-sectional studies utilizing DEXA scans and computed tomography, a 15%–65% prevalence of central lipohypertrophy was noted within 1 to 2 years of initiation of ART[70]. Patient self-report, in concert with physician examination, represent the earliest and best indicators of body contour changes. The latter are a major cause of both social stigmatization and reduced drug adherence.

Distinct clinical syndromes of fat redistribution can result, depending upon the particular drug or combination of drugs. In patients who developed lipohypertrophy, INSTIs were associated with increased weight

Downloaded for Anonymous User (n/a) at Egyptian Knowledge Bank from ClinicalKey.com by Elsevier on March 10, 2024. For personal use only. No other uses without permission. Copyright ©2024. Elsevier Inc. All rights reserved.

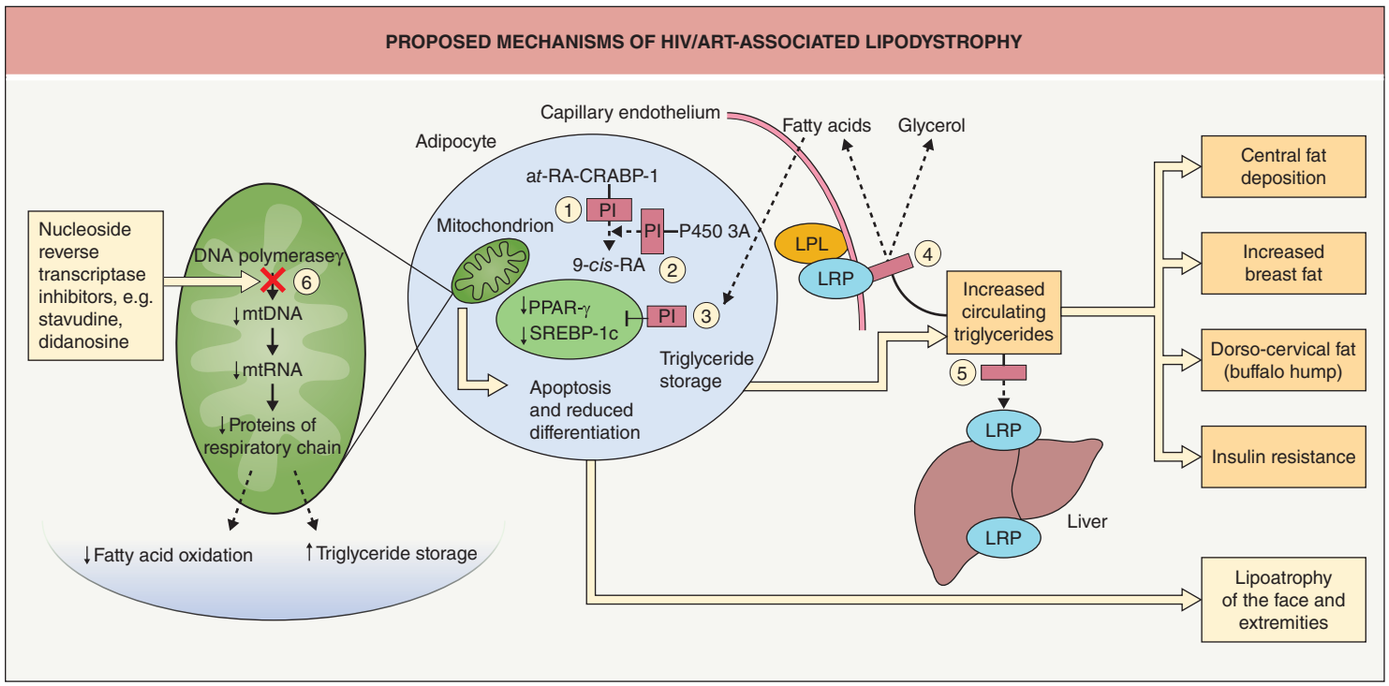

Fig. 101.14 Proposed mechanisms of HIV/ART-associated lipodystrophy. The combination of decreased PPAR-γ expression and decreased fatty acid oxidation capacity resulting from drug exposure could explain how these drugs cause adipocyte toxicity and lipoatrophy. See Table 101.6 for additional details. The numbers represent sites of drug effects. ART, antiretroviral therapy; *at*-RA, all-*trans*-retinoic acid; CRABP-1, cytoplasmic retinoic acid binding protein type 1; LPL, lipoprotein lipase; LRP, low-density lipoprotein receptor-related protein; mtRNA, mitochondrial RNA; mtDNA, mitochondrial DNA; PIs, protease inhibitors; PPAR-γ, peroxisome proliferator-activated receptor-γ; RXR, retinoid X receptor; SREBP-1c, sterol regulatory element-binding protein-1c. *Adapted from Carr A. HIV protease inhibitor-related lipodystrophy syndrome. Clin Infect Dis 2000;30:S135–42.*

MECHANISMS OF ANTIRETROVIRAL THERAPY (ART)-ASSOCIATED LIPOATROPHY			
	HIV drugs implicated	**Drug-induced effect**	**Cellular response**
↓ Adipocyte differentiation*	PIs, NRTIs	Defect in lamin A/C processing and/or RXR-PPAR-γ heterodimer activation decreases function of SREBP-1c & other downstream transcription factors	↓ Production of new mature fat cells → ↓ fat cell number
↑ Adipocyte apoptosis+	PIs, NRTIs	↑ TNF-α signaling (as well as mechanism described above for ↓ differentiation)	↑ Fat cell death → ↓ fat cell number
↑ Lipolysis*	PIs, NRTIs	↓ Expression of perilipin	↑ Release of stored TGs as FFAs and glycerol into circulation →↓ fat cell size
↓ Lipogenesis	PIs, NRTIs	↓ Expression and function of lipogenic SREBP-1c	↓ FFA uptake by adipocytes → ↓ fat cell size
Mitochondrial toxicity	NRTIs	Inhibition of mitochondrial DNA polymerase-γ	↑ Catabolic pathways (lipolysis), altered production of hormones and cytokines (↓ adiponectin, ↑ TNF-α), ↓ adipocyte differentiation, ↑ adipocyte apoptosis
*Also represent sequelae of mitochondrial toxicity.			

Table 101.6 Mechanisms of antiretroviral therapy (ART)-associated lipoatrophy. FFA, free fatty acids; HIV, human immunodeficiency virus; NRTI, nucleoside reverse transcriptase inhibitor; PI, protease inhibitor; PPAR-γ, peroxisome proliferator-activated receptor-γ; RXR, retinoid X receptor; SREBP-1c, sterol regulatory element-binding protein-1c; TG, triglycerides; TNF, tumor necrosis factor. *From refs. 60–62,64,65.*

gain compared to PIs and NNRTIs[72]. Amongst the NRTIs, tenofovir alafenamide led to more weight gain than did tenofovir disoproxil fumarate, abacavir, or zidovudine[72]. With regard to lipoatrophy, NRTIs, especially stavudine, were more likely to result in peripheral fat wasting. Of note, older NRTIs are associated with multiple complications related to mitochondrial toxicity, including myopathy, polyneuropathy, liver steatosis, pancreatitis, hyperlactatemia, bone marrow toxicity and a Fanconi-like syndrome.

Similar to inherited lipodystrophy syndromes, fat redistribution in HIV/ART-associated lipodystrophy may precede the development of metabolic complications. These include insulin resistance, diabetes, dyslipidemia, and bone disorders such as osteopenia, osteoporosis, and avascular necrosis. The insulin resistance may arise via either the direct effects of PIs on insulin-mediated whole-body glucose uptake or the indirect effects of dyslipidemia, mitochondrial toxicity, and changes in body fat composition. Adipocytokines, in particular leptin and adiponectin, affect insulin sensitivity, and low levels of both factors have been observed in HIV/ART-associated lipodystrophy[5,9,73]. Genetic variation in resistin production by adipose tissue is also implicated in HIV/ART-associated obesity and insulin resistance[74]. In HIV-infected patients receiving ART, the prevalence of metabolic syndrome has been reported to be 15%–25%, resulting in an increased risk for cardiovascular disease[40]. For example, the Data Collection on Adverse Events of Anti-HIV Drugs (DAD) study found an ~25% increase in the rate of myocardial infarctions per year during the first 4–6 years of ART exposure[75].

Immune Checkpoint Inhibitor-Associated Lipodystrophy

Two anti-PD-1 antibodies, nivolumab and pembrolizumab, have been associated with the development of lipodystrophy[76]. Following at least 10 months of administration, generalized lipoatrophy developed in

Downloaded for Anonymous User (n/a) at Egyptian Knowledge Bank from ClinicalKey.com by Elsevier on March 10, 2024. For personal use only. No other uses without permission. Copyright ©2024. Elsevier Inc. All rights reserved.

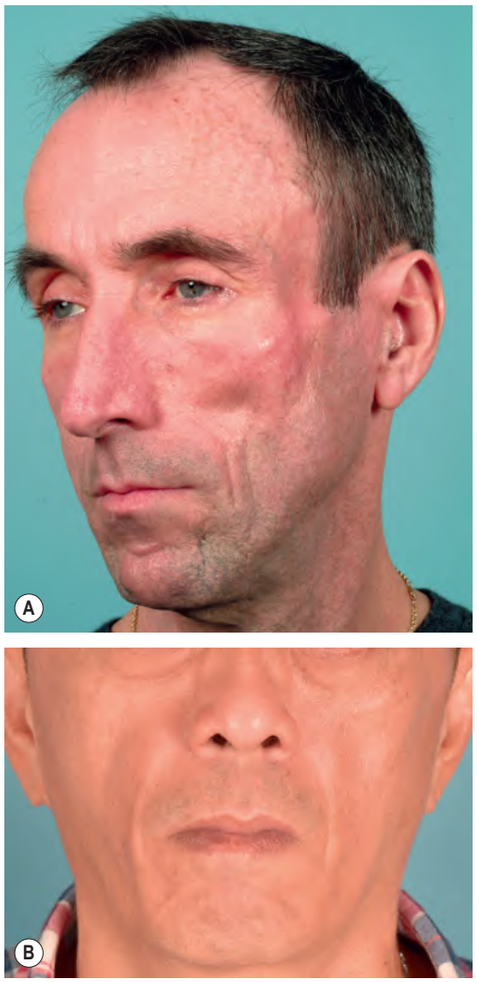

Fig. 101.15 HIV/ART-associated lipoatrophy. A The side view highlights the loss of temporal fat. **B** There is symmetric loss of buccal and parotid fat, resulting in prominent zygomata and a cachectic appearance, in a second patient. *A, Courtesy Ken Katz, MD; B, Courtesy National Skin Centre, Singapore.*

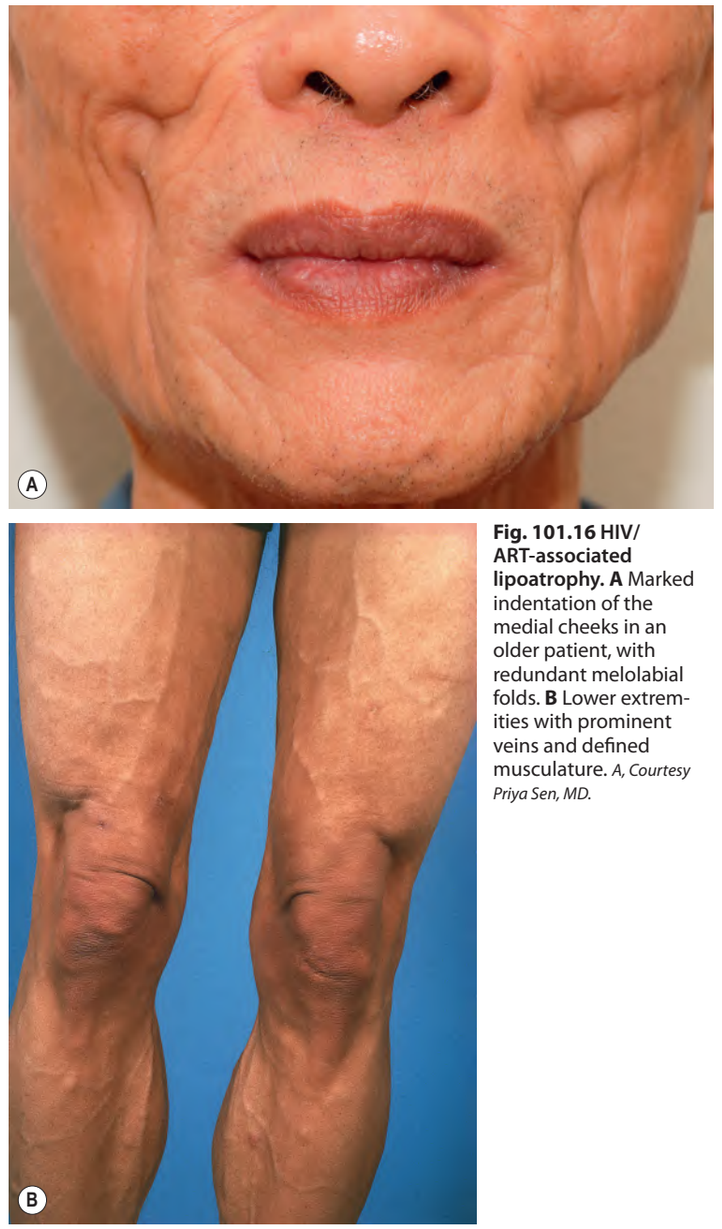

Fig. 101.16 HIV/ART-associated lipoatrophy. A Marked indentation of the medial cheeks in an older patient, with redundant melolabial folds. **B** Lower extremities with prominent veins and defined musculature. *A, Courtesy Priya Sen, MD.*

association with diabetes mellitus, insulin resistance, hypertriglyceridemia, and central obesity. These clinical manifestations persisted despite discontinuation of the medication.

POEMS Syndrome

Acquired partial lipodystrophy that preferentially affects the face is one of the more recently recognized cutaneous manifestations of POEMS syndrome (polyneuropathy, organomegaly, endocrinopathy, monoclonal gammopathy, and skin changes). Symmetric lipoatrophy of the face has been noted in up to half of patients[77]. Treatment of the underlying paraproteinemia usually arrests its progression but does not lead to reversal.

Allogeneic Hematopoietic Stem Cell Transplantation-Associated Lipodystrophy

Acquired partial lipodystrophy and associated metabolic abnormalities have been observed following allogeneic hematopoietic stem cell transplantation, primarily in children[78]. The cutaneous findings resemble those of FPLD with lipoatrophy of the gluteal region and extremities and retention of fat in the face and abdomen. It may reflect a graft-versus-host (GVHD) reaction at the adipocyte level.

Additional figures available in our eBook (see inside front cover for access code).

REFERENCES

1. Mitchell SW. Singular case of absence of adipose matter in the upper half of the body. *Am J Med Sci*. 1885;90:105–106.
2. Seip M, Trygstad O. Generalized lipodystrophy, congenital and acquired (lipoatrophy). *Acta Paediatr Suppl*. 1996;413:2–28.
3. Carr A, Samaras K, Burton S, et al. A syndrome of peripheral lipodystrophy, hyperlipidemia and insulin resistance in patients receiving HIV protease inhibitors. *AIDS*. 1998;12:F51–F58.
4. Wauters M, Considine RB, van Gaal LF. Human leptin: from an adipocyte hormone to an endocrine mediator. *Eur J Endocrinol*. 2000;143:293–311.
5. Vigouroux C, Maachi M, Nguyen TH, et al. Serum adipocytokines are related to lipodystrophy and metabolic disorders in HIV-infected men under antiretroviral therapy. *AIDS*. 2003;17:1503–1511.
6. Simha V, Garg A. Lipodystrophy: lessons in lipid and energy metabolism. *Curr Opin Lipidol*. 2006;17:162–169.
7. Weyer C, Funahashi T, Tanaka S, et al. Hypoadiponectinemia in obesity and type 2 diabetes: close association with insulin resistance and hyperinsulinemia. *J Clin Endocrinol Metab*. 2001;86:1930–1935.
8. Haque WA, Shimomura I, Matsuzawa Y, Garg A. Serum adiponectin and leptin levels in patients with lipodystrophies. *J Clin Endocrinol Metab*. 2002;87:2395–2398.
9. Addy CL, Gavrila A, Tsiodras S, et al. Hypoadiponectinemia is associated with insulin resistance, hypertriglyceridemia, and fat redistribution in human immunodeficiency virus-infected patients treated with highly active antiretroviral therapy. *J Clin Endocrinol Metab*. 2003;88:627–636.
10. Nagy S, Tsiodras S, Martin L, et al. Leptin is independently associated with lipodystrophy in HIV-1 infected patients treated with HAART. *Clin Infect Dis*. 2003;36:795–802.
11. Shimomura I, Hammer RE, Ikemoto S, et al. Leptin reverses insulin resistance and diabetes mellitus in mice with congenital lipodystrophy. *Nature*. 1999;401:73–76.

Downloaded for Anonymous User (n/a) at Egyptian Knowledge Bank from ClinicalKey.com by Elsevier on March 10, 2024. For personal use only. No other uses without permission. Copyright ©2024. Elsevier Inc. All rights reserved.

12. Chong AY, Lupsa BC, Cochran EK, Gorden P. Efficacy of leptin therapy in the different forms of human lipodystrophy. *Diabetologia*. 2010;53:27–35.
13. Javor ED, Cochran EK, Musso C, et al. Long-term efficacy of leptin replacement in patients with generalized lipodystrophy. *Diabetes*. 2005;54:1994–2002.
14. Agarwal AK, Garg A. Genetic basis of lipodystrophies and management of metabolic complications. *Annu Rev Med*. 2006;57:297–311.
15. Kim CA, Delepine M, Boutet E, et al. Association of a homozygous nonsense caveolin-1 mutation with Berardinelli-Seip congenital lipodystrophy. *J Clin Endocrinol Metab*. 2008;93:1129–1134.
16. Patni N, Vuitch F, Garg A. Postmortem findings in a young man with congenital generalized lipodystrophy type 4 due to CAVIN1 mutations. *J Clin Endocrinol Metab*. 2019;104:957–960.
17. Agarwal AK, Simha V, Oral SA, et al. Phenotypic and genetic heterogeneity in congenital generalized lipodystrophy. *J Clin Endocrinol Metab*. 2003;88:4840–4847.
18. van de Warrenburg BP, Scheffer H, van Eijk JJ, et al. *BSCL2* mutations in two Dutch families with overlapping Silver syndrome-distal hereditary motor neuropathy. *Neuromuscul Disord*. 2006;16:122–125.
19. Peters JM, Barnes R, Bennett L, et al. Localization of the gene for familial partial lipodystrophy (Dunnigan variety) to chromosome 1q21–22. *Nat Genet*. 1998;18:292–295.
20. Hegele RA, Cao H, Huff MW, Anderson CM. LMNA R482Q mutation in partial lipodystrophy associated with reduced plasma leptin concentration. *J Clin Endocrinol Metab*. 2000;855:3089–3093.
21. Vigouroux C, Guénantin AC, Vatier C, et al. Lipodystrophic syndromes due to LMNA mutations: recent developments on biomolecular aspects, pathophysiological hypotheses and therapeutic perspectives. *Nucleus*. 2018;9:235–248.
22. Garg A, Vinaitheerthan M, Weatherall PT, Bowcock AM. Phenotypic heterogeneity in patients with familial partial lipodystrophy (Dunnigan variety) related to the site of missense mutations in lamin A/C gene. *J Clin Endocrinol Metab*. 2001;86:59–65.
23. Agarwal AK, Garg A. A novel heterozygous mutation in peroxisome proliferator-activated receptor-gamma gene in a patient with familial partial lipodystrophy. *J Clin Endocrinol Metab*. 2002;87:408–411.
24. Gandotra S, Le Dour C, Bottomley W, et al. Perilipin deficiency and autosomal dominant partial lipodystrophy. *N Engl J Med*. 2011;364:740–748.
25. Kozusko K, Tsang V, Bottomley W, et al. Clinical and molecular characterization of a novel PLIN1 frameshift mutation identified in patients with familial partial lipodystrophy. *Diabetes*. 2015;69:299–310.
26. Rubio-Cabezas O, Puri V, Murano I, et al. Partial lipodystrophy and insulin resistant diabetes in a patient with a homozygous nonsense mutation in CIDEC. *EMBO Mol Med*. 2009;1:280–287.
27. Agarwal AK, Fryns JP, Auchus RJ, Garg A. Zinc metalloproteinase, ZMPSTE24, is mutated in mandibuloacral dysplasia. *Hum Mol Genet*. 2003;12:1995–2001.
28. Corvillo F, Akinci B. An overview of lipodystrophy and the role of the complement system. *Mol Immunol*. 2019;112:223–232.
29. Misra A, Garg A. Clinical features and metabolic derangements in acquired generalized lipodystrophy: case reports and review of the literature. *Medicine (Baltimore)*. 2003;82:129–146.
30. Hubler A, Abendroth K, Keiner T, et al. Dysregulation of insulin like growth factors in a class of generalized acquired lipoatrophic diabetes mellitus (Lawrence syndrome) connected with autoantibodies against adipocyte membranes. *Exp Clin Endocrinol Diabetes*. 1998;106:79–84.
31. Corvillo F, Aparicio V, López-Lera A, et al. Autoantibodies against perilipin 1 as a cause of acquired generalized lipodystrophy. *Front Immunol*. 2018;199:2142.
32. Halpern B, Nery M, Pereira MAA. Case report of acquired generalized lipodystrophy associated with common variable immunodeficiency. *J Clin Endocrinol Metab*. 2018;103:2807–2810.
33. Gao J, Li Y, Fu X, Luo X. A Chinese patient with acquired partial lipodystrophy caused by a novel mutation with LMNB2 gene. *J Pediatr Endocrinol Metab*. 2012;25:375–377.
34. Nguyen AL, Morren M, van Doorn R. Severe lipodystrophy following prolonged subcutaneous administration of antisense oligonucleotides. *JAMA Dermatol*. 2019;155:1084–1086.
35. Raile K, Noelle V, Landgraf R, Schwarz HP. Insulin antibodies are associated with lipoatrophy but also with lipohypertrophy in children and adolescents with type 1 diabetes. *Exp Clin Endocrinol Diabetes*. 2001;109:393–396.
36. Gómez-Espejo C, Pérez-Bernal A, Camacho-Martínez F. A new case of semicircular lipoatrophy associated with repeated external microtraumas and review of the literature. *J Eur Acad Dermatol Venereol*. 2005;19:459–461.
37. Becker C, Barbulescu K, Hildner K, et al. Activation and methotrexate-mediated suppression of the TNF alpha promoter in T cells and macrophages. *Ann N Y Acad Sci*. 1998;859:311–314.
38. Dahl PR, Zalla MJ, Winkelmann RK. Localized involutional lipoatrophy: a clinicopathologic study of 16 patients. *J Am Acad Dermatol*. 1996;35:523–528.
39. Okita H, Ohtsuka T, Yamakage A, Yamazaki S. Lipodystrophia centrifugalis abdominalis infantilis – immunohistochemical demonstration of an apoptotic process in the degenerating fatty tissue. *Dermatology*. 2000;201:370–372.
40. Hussain I, Patni N, Garg A. Lipodystrophies, dyslipidaemias and atherosclerotic cardiovascular disease. *Pathology*. 2019;51:202–212.
41. Zou W, Rohatgi N, Brestoff JR, et al. Congenital lipodystrophy induces severe osteosclerosis. *PLoS Genet*. 2019;15e1008244.
42. Lima JG, Nobrega LHC, Lima NN, et al. Causes of death in patients with Berardinelli-Seip congenital generalized lipodystrophy. *PLoS One*. 2018;8:13. e0199052.
43. Chait A, Eckel RH. The chylomicronemia syndrome is most often multifactorial: a narrative review of causes and treatment. *Ann Intern Med*. 2019;170:626–34..
44. Cardis MA, Montealegre Sanchez GA, Goldbach-Mansky R, et al. Recurrent fevers, progressive lipodystrophy, and annular plaques in a child. *J Am Acad Dermatol*. 2019;80:291–295.
45. Kanazawa N, Honda-Ozaki F, Saito MK. Induced pluripotent stems cells representing Nakajo-Nishimura syndrome. *Inflamm Regen*. 2019;39:1835–1850.
46. Brehm A, Krüger E. Dysfunction in protein clearance by the proteasome: impact on autoinflammatory diseases. *Semin Immunopathol*. 2015;37:323–333.
47. Torrelo A, Noguera-Morel L, Hernández-Martín A, et al. Recurrent lipoatrophic panniculitis of children. *J Eur Acad Dermatol Venereol*. 2017;31:536–543.
48. Misra A, Peethambaram A, Garg A. Clinical features and metabolic and autoimmune derangements in acquired partial lipodystrophy. Report of 35 cases and review of the literature. *Medicine (Baltimore)*. 2004;83:18–34.
49. Lamam Bennani Z, Boussofara L, Denguezli M, et al. Annular lipoatrophy of the ankles. *Ann Dermatol Venereol*. 2011;138:512–515.
50. Imamura S. Lipodystrophia centrifugalis abdominalis infantilis: statistical analysis of 168 cases. *Pediatr Dermatol*. 2012;29:437–441.
51. Chang SE, Bae GY, Jeong YI, et al. Lipodystrophia centrifugalis abdominalis in Korea. *Pediatr Dermatol*. 2004;21:538–541.
52. Gupta SS, Gupta KS, Gathe SS, et al. Clinical implications of lipohypertrophy among people with type 1 diabetes in India. *Diabetes Technol Ther*. 2018;20:483–491.
53. Peters MS, Winklemann RK. The histopathology of localized lipoatrophy. *Br J Dermatol*. 1986;114:27–36.
54. Camacho D, Pielasinski U, Revelles JM, et al. Diffuse lower limb lipoatrophy. *J Cutan Pathol*. 2011;38:270–274.
55. Altay C, Seçil M, Demir T, et al. Determining residual adipose tissue characteristics with MRI in patients with various subtypes of lipodystrophy. *Diagn Interv Radiol*. 2017;23:428–434.
56. Akinci B, Meral R, Oral EA. Update on therapeutic options in lipodystrophy. *Curr Diab Rep*. 2018;18:139.
57. Brown RJ, Araujo-Vilar D, Cheung PT, et al. The diagnosis and management of lipodystrophy syndromes: a multi-society practice guideline. *J Clin Endocrinol Metab*. 2016;101:4500–4511.
58. Wolfort FG, Cetrulo CL, Nevarre DR. Suction-assisted lipectomy for lipodystrophy syndromes attributed to HIV-protease inhibitor use. *Plast Reconstr Surg*. 1999;104:1814–1820.
59. Binder WJ, Bloom DC. The use of custom-designed midfacial and submalar implants in the treatment of facial wasting syndrome. *Arch Facial Plast Surg*. 2004;6:394–397.
60. Akinci B, Sahinoz M, Oral E, et al. *Lipodystrophy syndromes: presentation and treatment. Endotext [Internet]*. South Dartmouth: MDText.com, Inc; 2000.
61. Macallan DC, Baldwin C, Mandalia S, et al. Treatment of altered body composition in HIV-associated lipodystrophy: comparison of rosiglitazone, pravastatin, and recombinant human growth hormone. *HIV Clin Trials*. 2008;9:254–268.
62. Melvin A, Adams C, Flanagan C, et al. Roux-en-Y gastric bypass surgery in the management of familial partial lipodystrophy type 1. *J Clin Endocrinol Metab*. 2017;102:3616–3620.
63. Brown RJ, Oral EA, Cochran E, et al. Long-term effectiveness and safety of metreleptin in the treatment of patients with generalized lipodystrophy. *Endocrine*. 2018;60:479–489.
64. Shibata Y, Nakatsuka A, Eguchi J, et al. Acquired partial lipoatrophy as graft-versus-host disease and treatment with metreleptin: two case reports. *J Med Case Rep*. 2018;1412:368.
65. Bacchi VF, Maillet F, Berlan L, et al. Neutralising antibodies against C3NeF in intravenous immunoglobulin. *Lancet*. 1992;340:63–64.
66. Grigem S, Fischer-Posovszky P, Debatin KM, et al. The effect of the HIV protease inhibitor ritonavir on proliferation, differentiation, lipogenesis, gene expression and apoptosis of human preadipocytes and adipocytes. *Horm Metab Res*. 2005;37:602–609.
67. Caron M, Auclair M, Lagathu C, et al. The HIV-1 NRTI stavudine and zidovudine alter adipocyte functions *in vitro*. *AIDS*. 2004;18:2127–2136.
68. Brinkman K, Smeitink I, Romijn J, Reiss P. Mitochondrial toxicity induced by NRTI is a key factor in the pathogenesis of ART-related lipodystrophy. *Lancet*. 1999;354:1112–1115.
69. Alikhani A, Morin H, Matte S, et al. Association between lipodystrophy and length of exposure to ARTs in adult HIV-1 infected patients. *BMC Infect Dis*. 2019;1819:820.
70. Miller J, Carr A, Emery S, et al. HIV lipodystrophy: prevalence, severity and correlates of risk in Australia. *HIV Med*. 2003;4:293–301.
71. Lichtenstein KA. Refining lipodystrophy syndrome. *J Acquir Immune Defic Syndr*. 2005;39:395–400.
72. Sax PE, Erlandson KM, Lake JE, et al. Weight gain following initiation of antiretroviral therapy: risk factors in randomized comparative clinical trials. *Clin Infect Dis*. 2020;71:1379–1389.
73. Sweeney LL, Brennan AM, Mantzoros CS. The role of adipokines in relation to HIV lipodystrophy. *AIDS*. 2007;21:895–904.
74. Ranade K, Geese WJ, Noor M, et al. Genetic analysis implicates resistin in HIV lipodystrophy. *AIDS*. 2008;22:1561–1568.
75. Friis-Møller N, Weber R, Reiss P, et al. DAD study group. Cardiovascular disease risk factors in HIV patients – association with antiretroviral therapy. Results from the DAD study. *AIDS*. 2003;17:1179–1193.
76. Haddad N, Vidal-Trecan T, Baroudjian B, et al. Acquired generalized lipodystrophy under immune checkpoint inhibition. *Br J Dermatol*. 2020;182:477–480.
77. Barete S, Mouawad R, Choquet S, et al. Skin manifestations and vascular endothelial growth factor levels in POEMS syndrome: impact of autologous hematopoietic stem cell transplantation. *Arch Dermatol*. 2010;146:615–623.
78. Hosokawa M, Shibata H, Hosokawa T, et al. Acquired partial lipodystrophy with metabolic disease in children following hematopoietic stem cell transplantation: a report of two cases and a review of the literature. *J Pediatr Endocrinol Metab*. 2019;32:537–541.

Downloaded for Anonymous User (n/a) at Egyptian Knowledge Bank from ClinicalKey.com by Elsevier on March 10, 2024. For personal use only. No other uses without permission. Copyright ©2024. Elsevier Inc. All rights reserved.

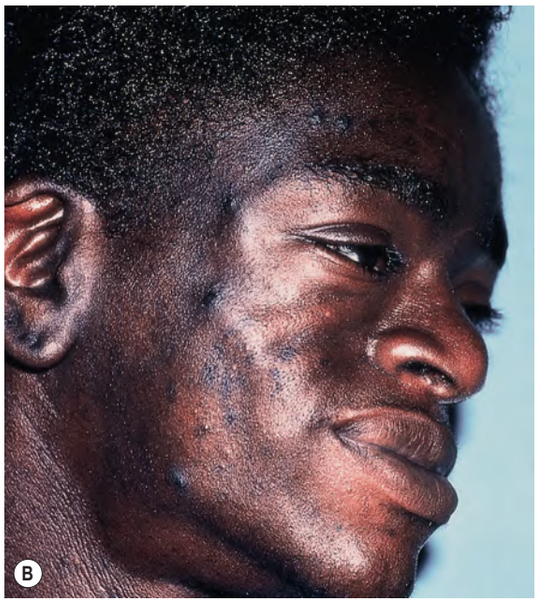

eFig. 101.1 Congenital generalized lipodystrophy syndrome. **A** Extensive acanthosis nigricans, facial and extremity lipodystrophy, and muscular habitus. **B** Close-up view demonstrating loss of buccal and temporal fat. *Courtesy Kenneth E. Greer, MD.*

eFig. 101.3 Congenital generalized lipodystrophy syndrome (Berardinelli–Seip syndrome). Extensive acanthosis nigricans. *Courtesy Edward Cowen, MD.*

eFig. 101.2 Congenital generalized lipodystrophy (Berardinelli–Seip syndrome). This woman has extensive acanthosis nigricans, well-defined muscles, prominent superficial veins and clitoromegaly. *Courtesy Regional Dermatology Training Centre, Moshi, Tanzania.*

Downloaded for Anonymous User (n/a) at Egyptian Knowledge Bank from ClinicalKey.com by Elsevier on March 10, 2024. For personal use only. No other uses without permission. Copyright ©2024. Elsevier Inc. All rights reserved.

eFig. 101.4 HIV/ART-associated lipodystrophy. The side view highlights the loss of temporal fat. *Courtesy National Skin Centre, Singapore*.

eFig. 101.5 Facial lipoatrophy due to lupus panniculitis. *Courtesy Jeffrey P. Callen, MD*.

Downloaded for Anonymous User (n/a) at Egyptian Knowledge Bank from ClinicalKey.com by Elsevier on March 10, 2024. For personal use only. No other uses without permission. Copyright ©2024. Elsevier Inc. All rights reserved.